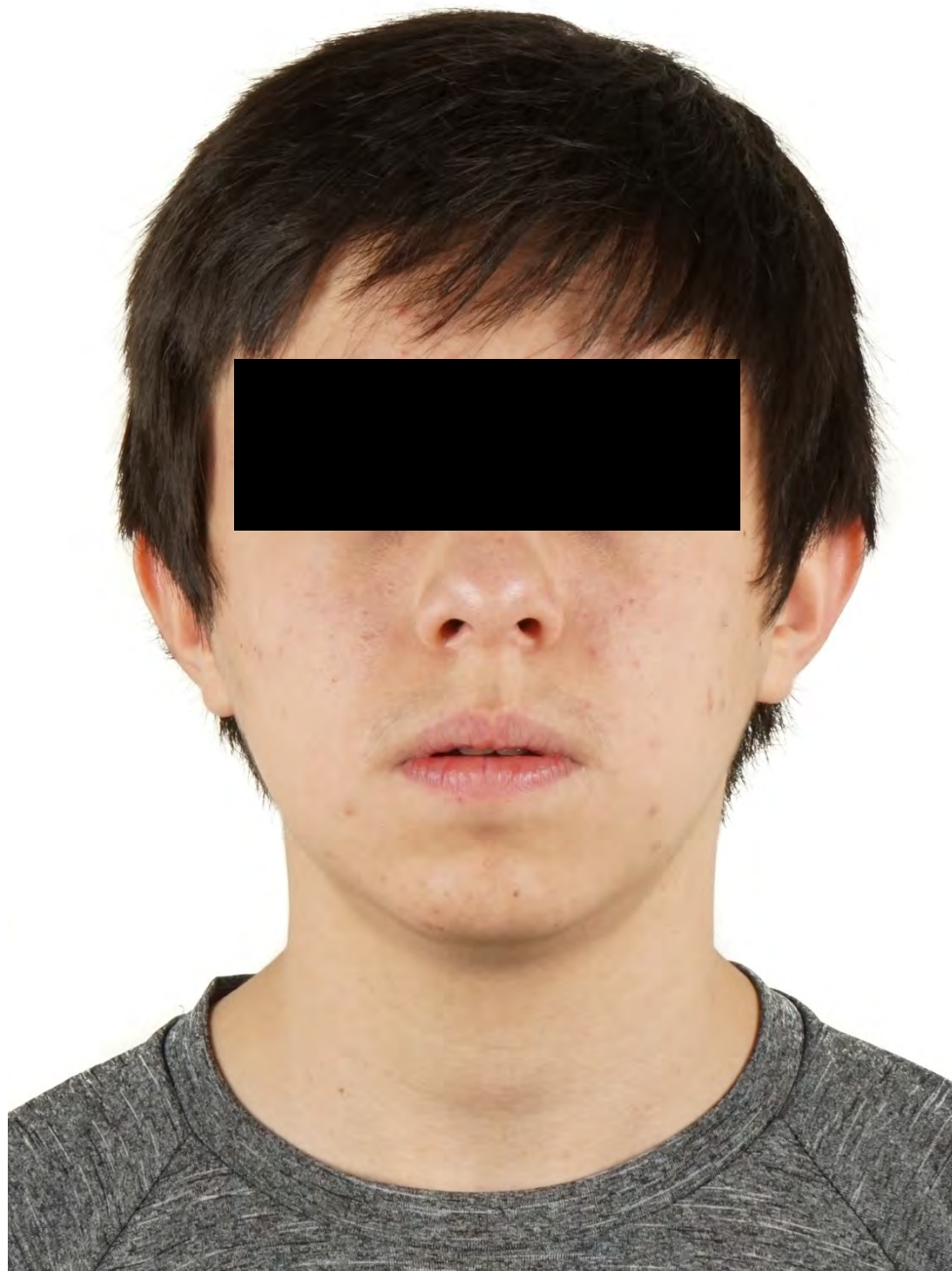


ICF3D

TECNOLOGÍA DIGITAL EN ODONTOLOGÍA

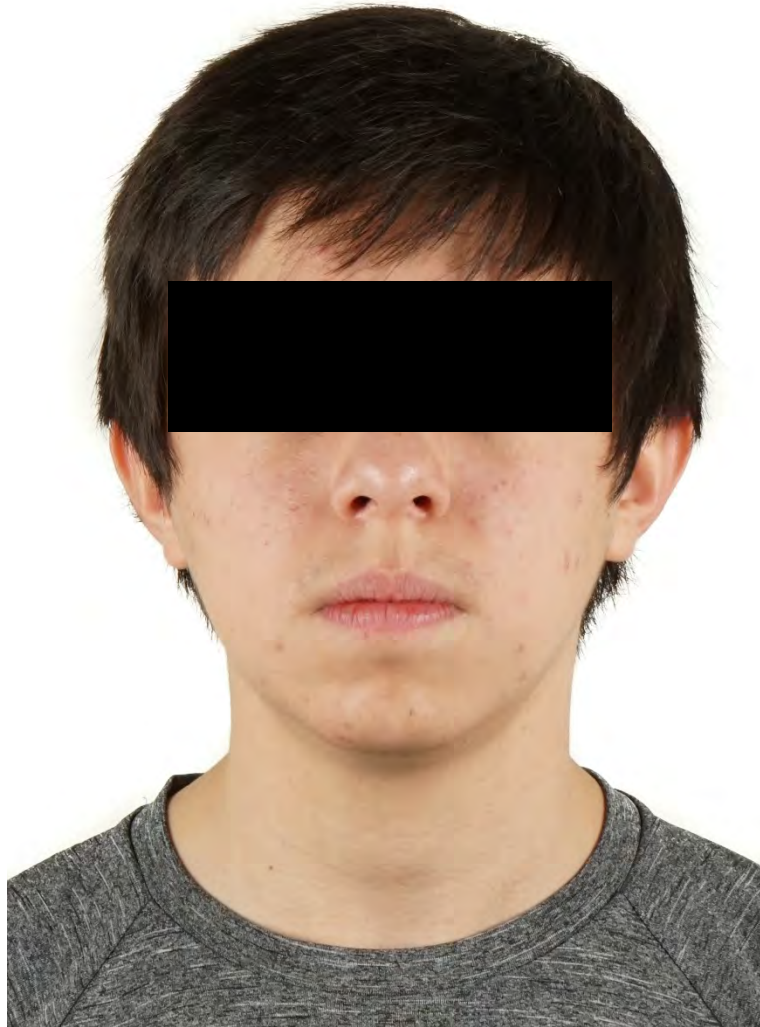Paciente: Martín Ramos Villela
Dra. Pamela Agurto

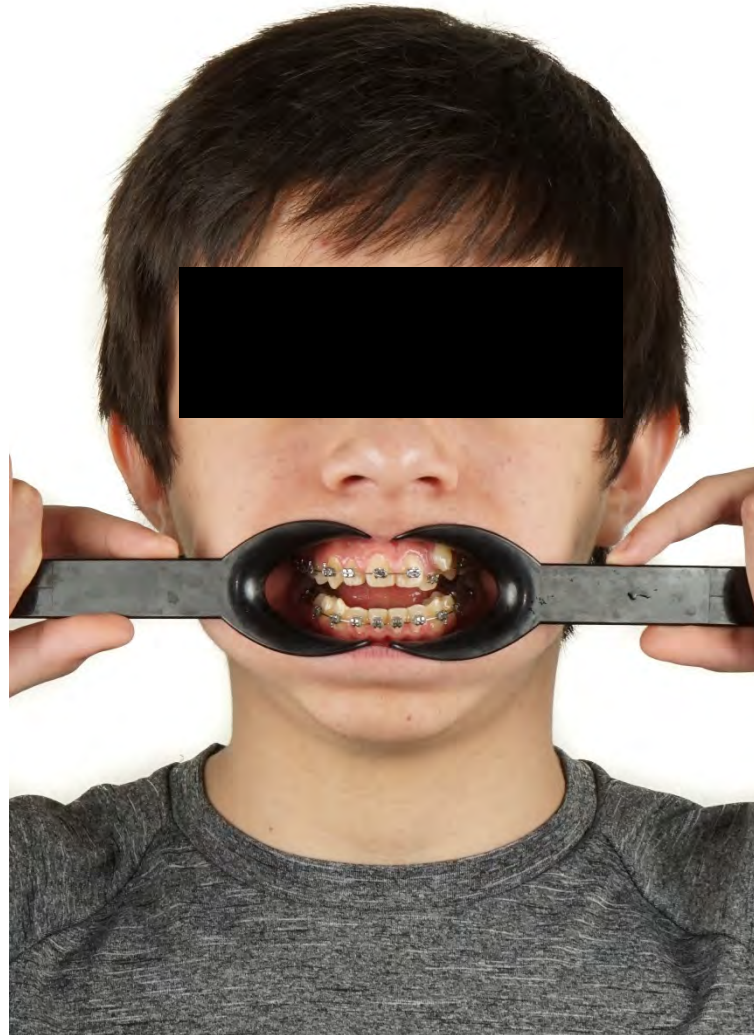
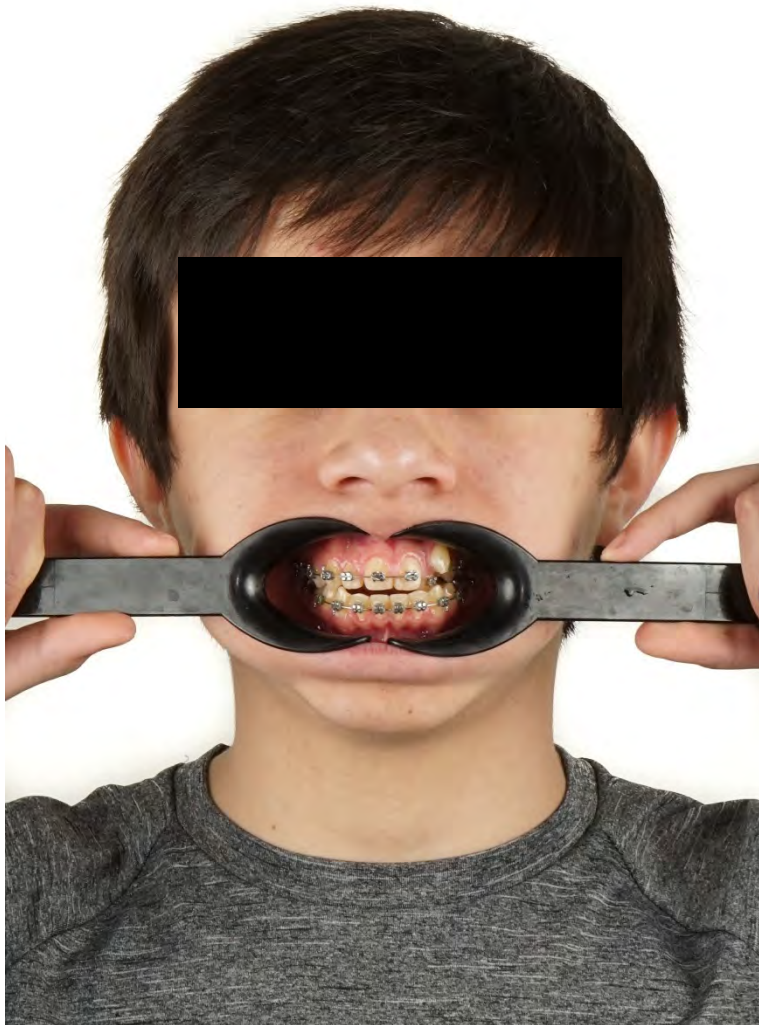
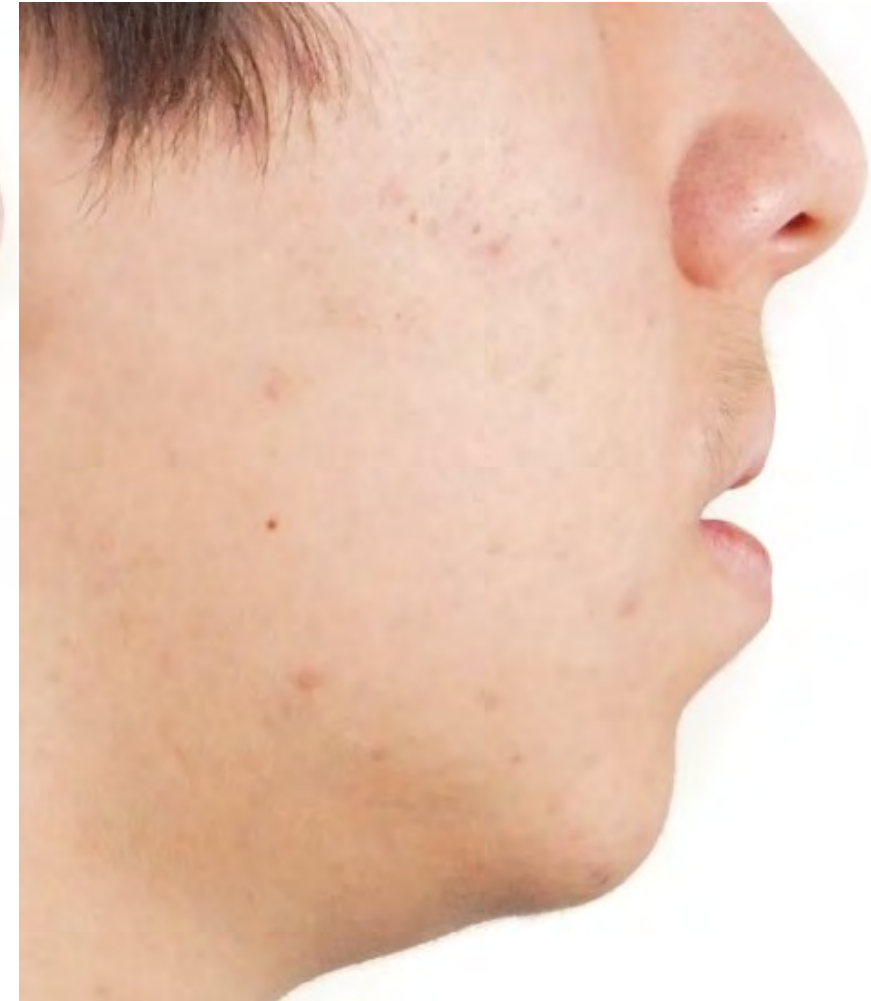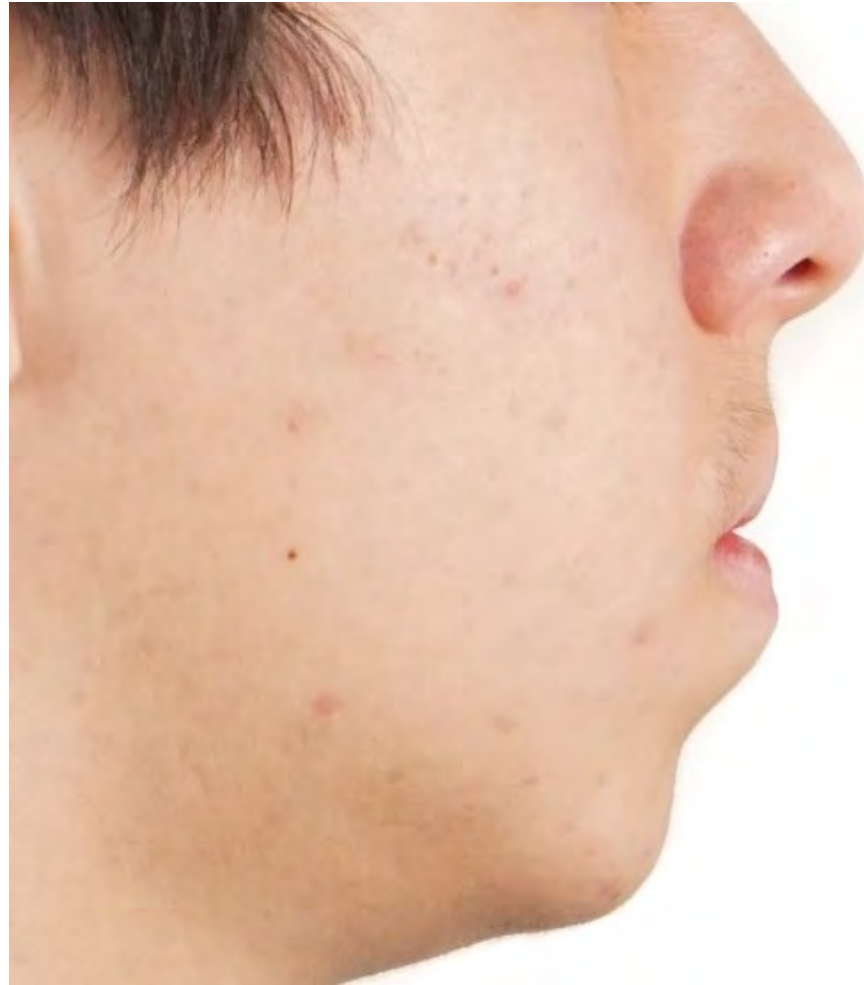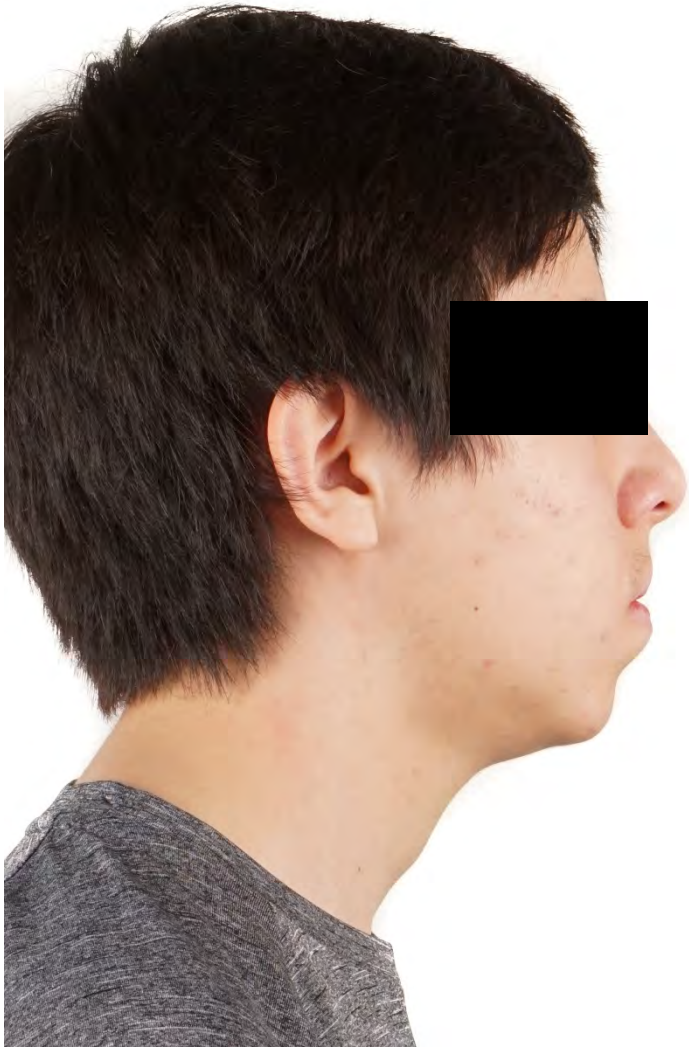ICF3D
TECNOLOGÍA DIGITAL EN ODONTOLOGÍA

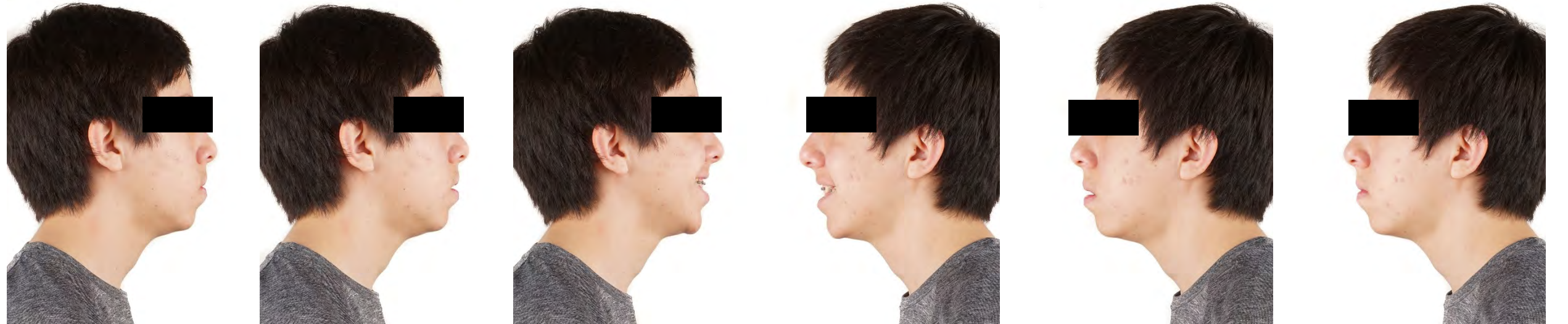
Información del caso

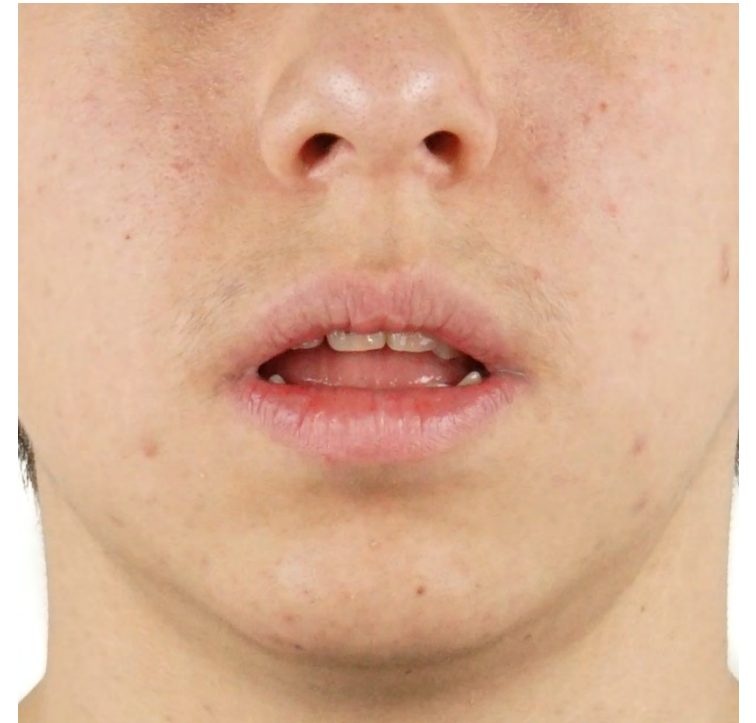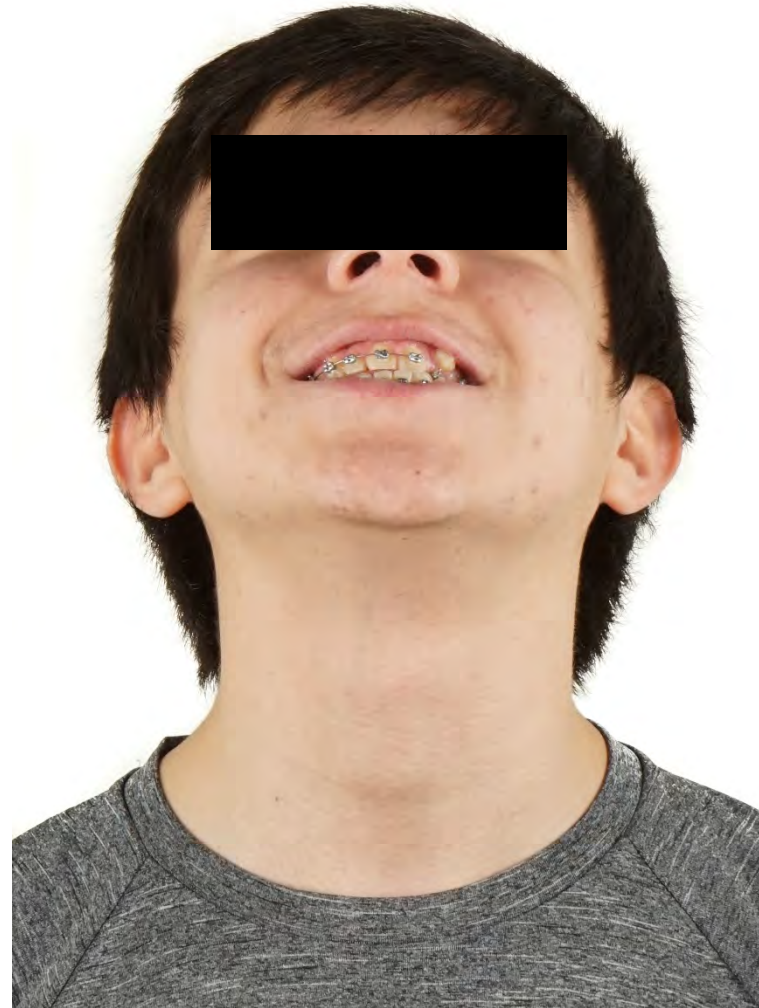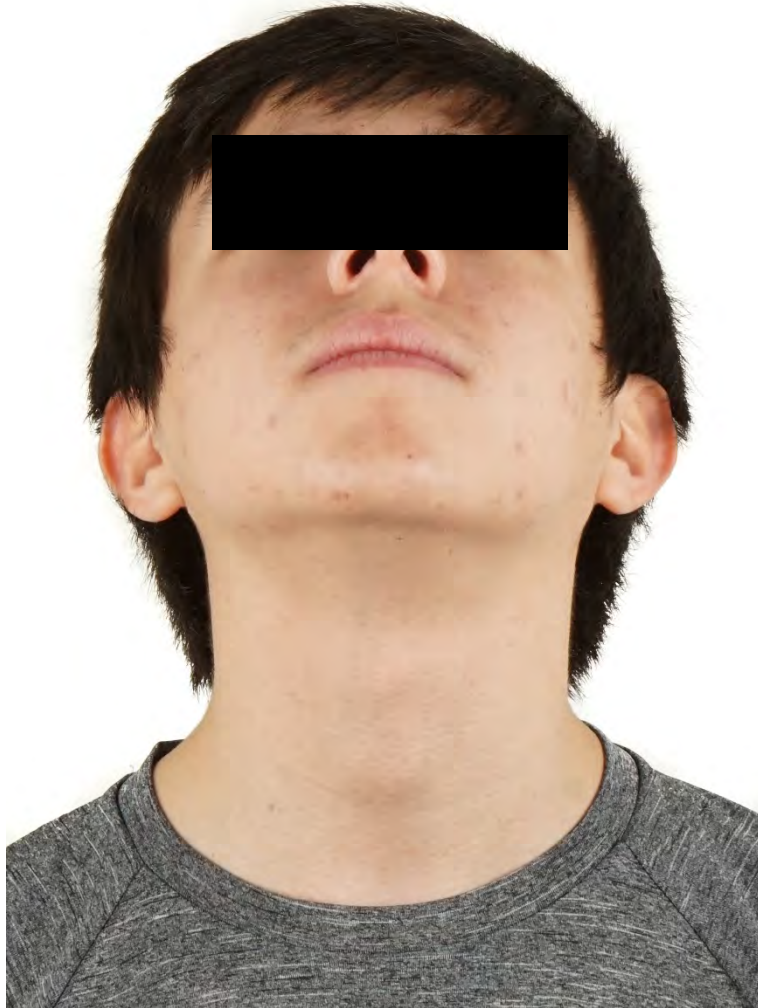Martín Ramos Villela
18 de Octubre del 2006
Perfil no coincide con oclusión.

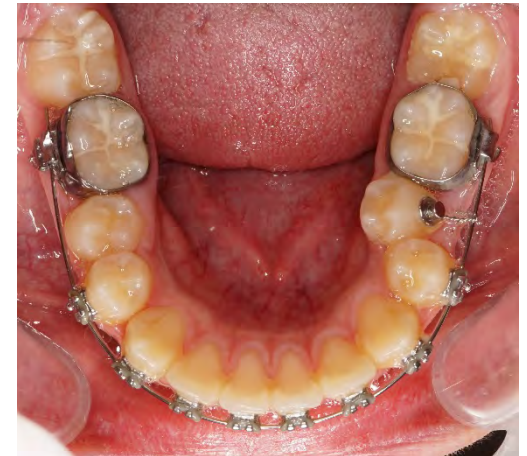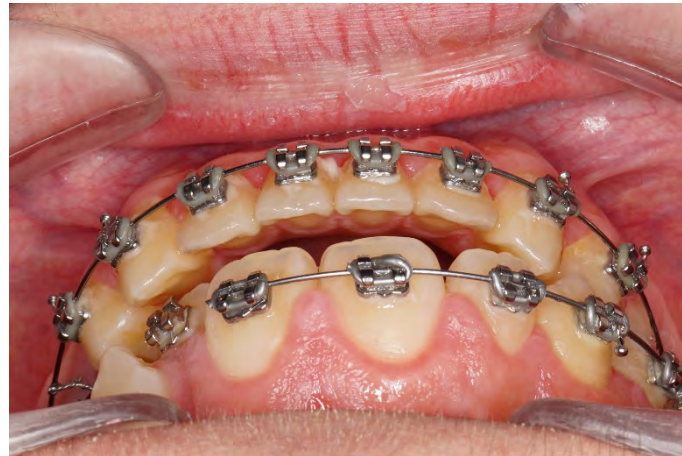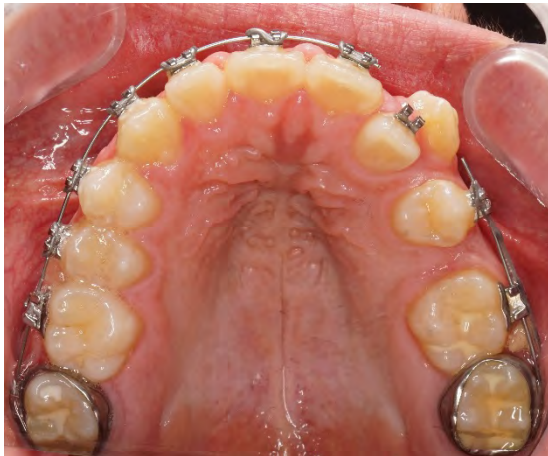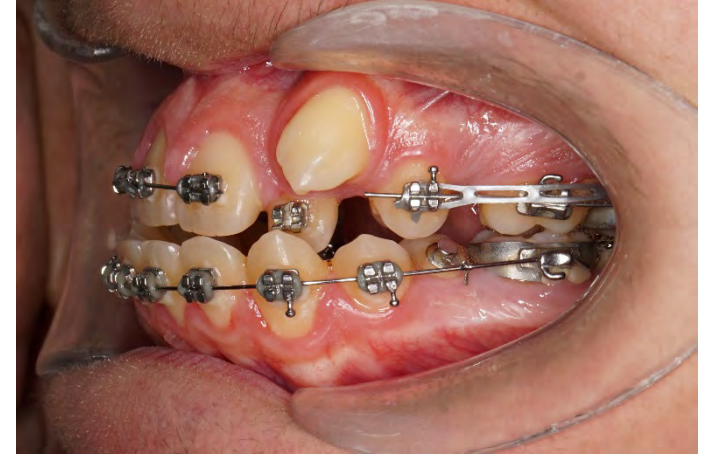



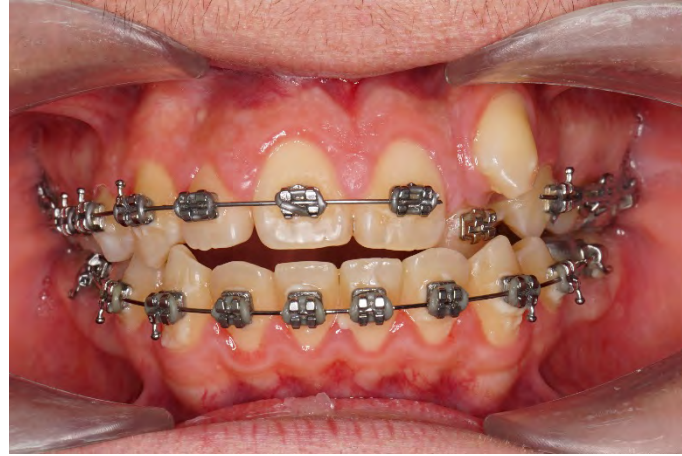
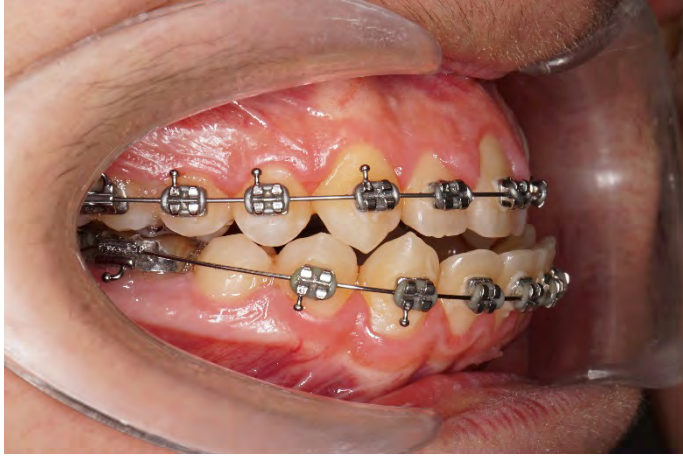


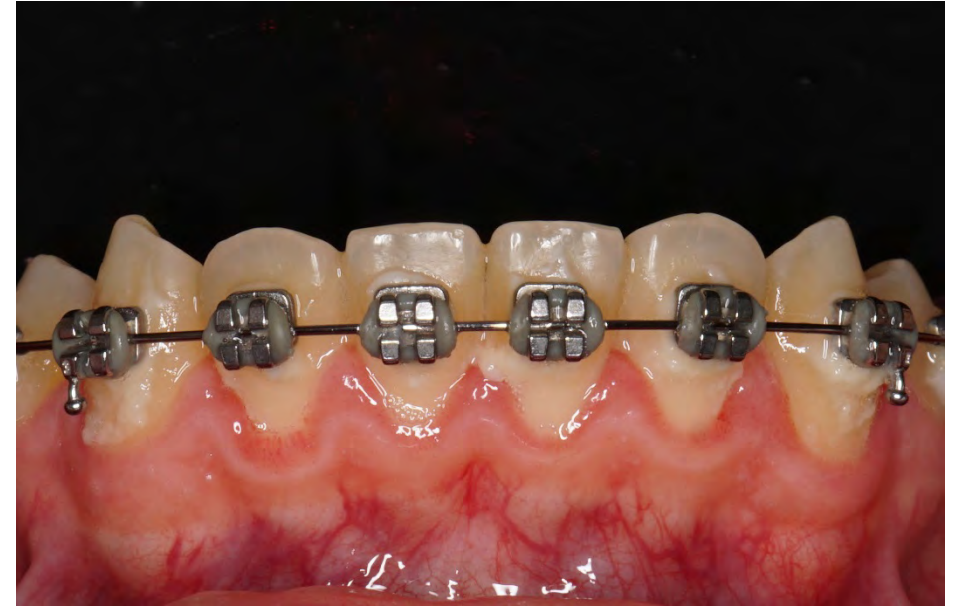
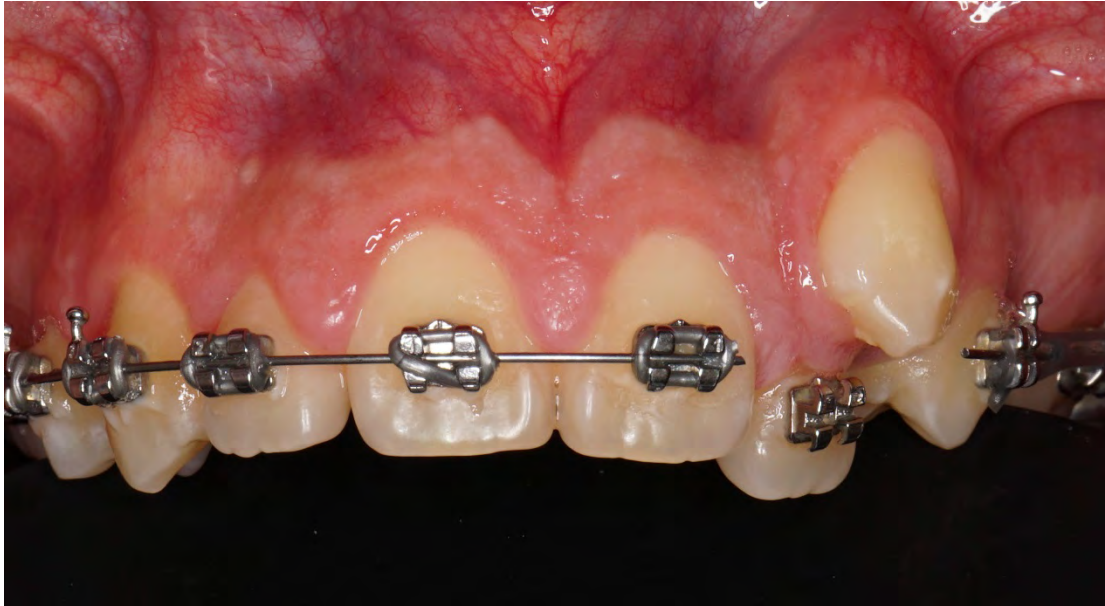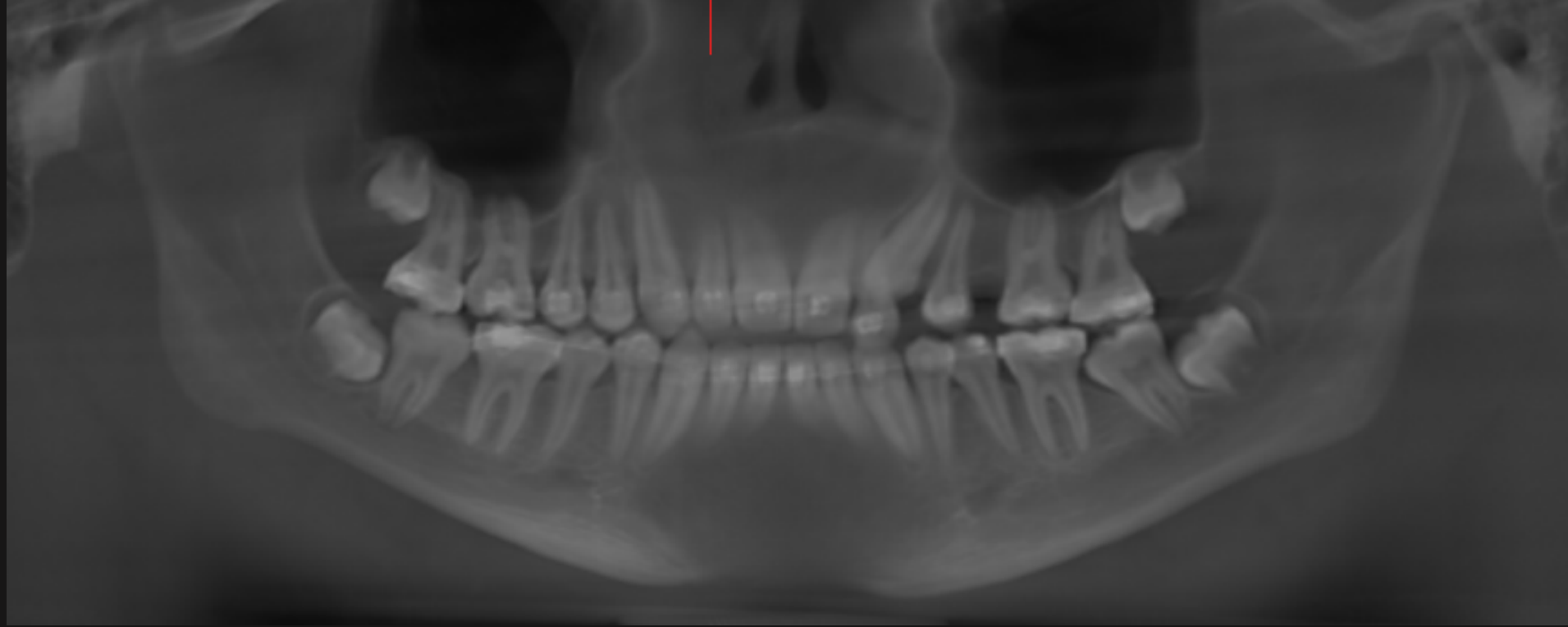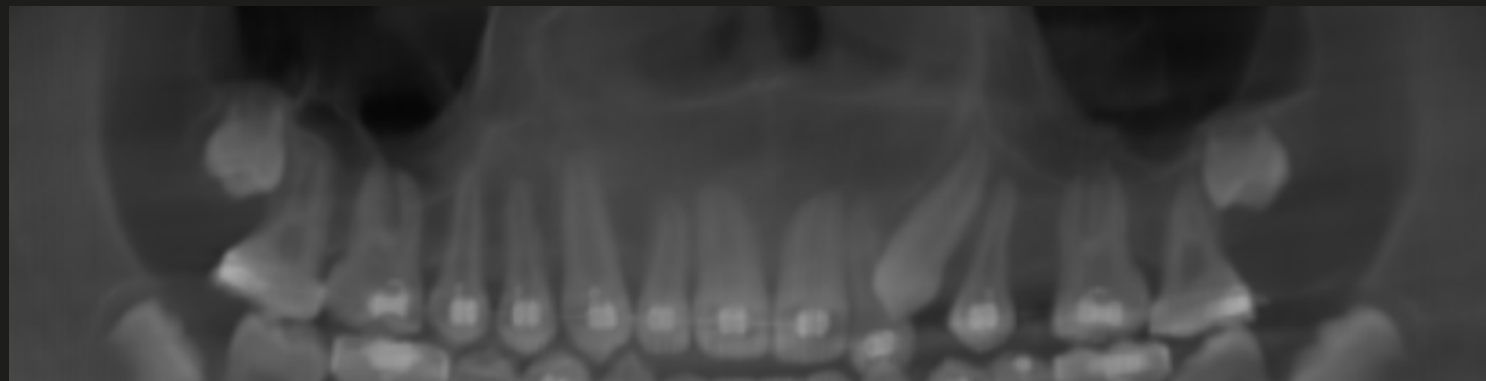








CORTES EJE DENTARIO SUPERIOR



DTE 1.8

DTE 1.7

DTE 1.6


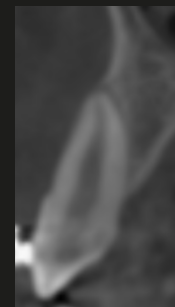
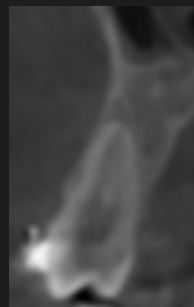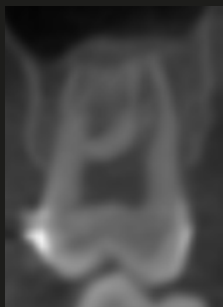

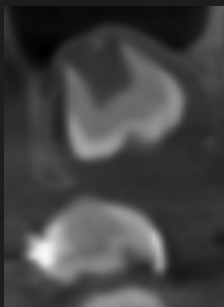
DTE 1.5

DTE 1.4

DTE 1.3

DTE 1.2

DTE 1.1



DTE 2.1

DTE 2.2

DTE 2.3

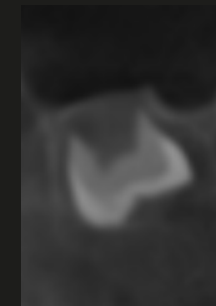
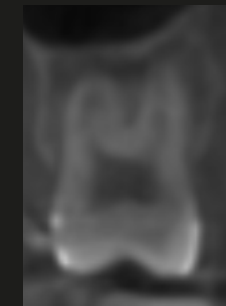
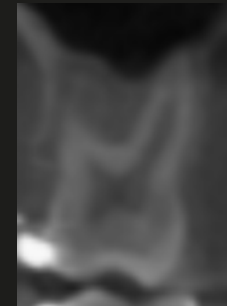
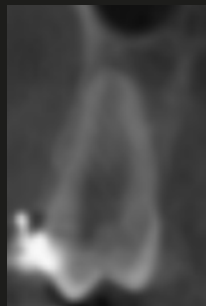
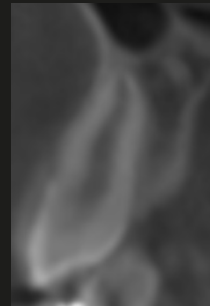
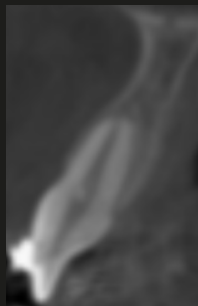
DTE 2.4

DTE 2.5

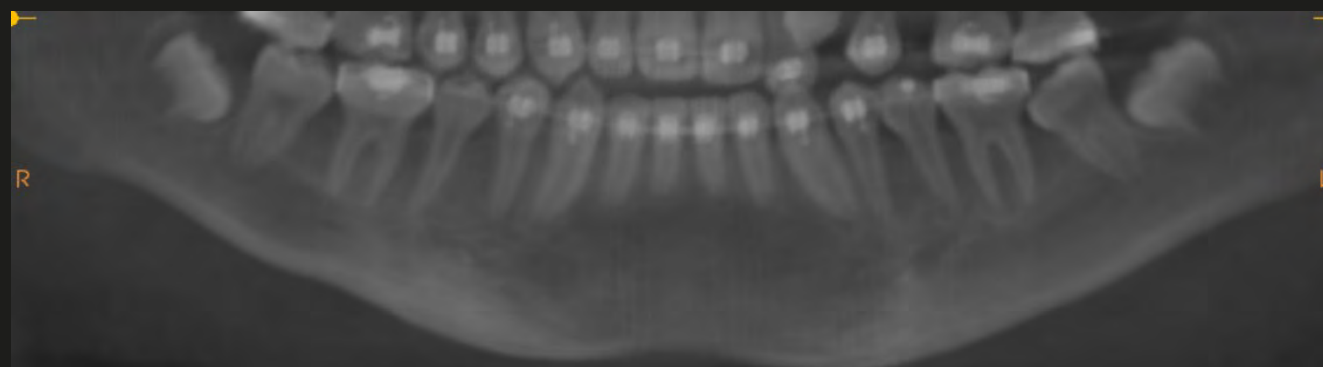DTE 2.6

DTE 2.7

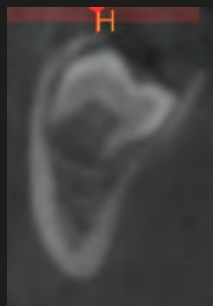
DTE 2.8



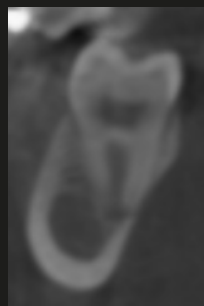CORTES EJE DENTARIO INFERIOR



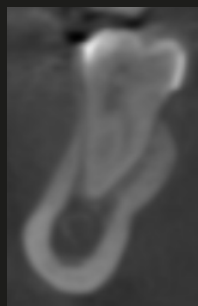
DTE 4.8



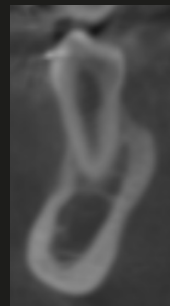
DTE 4.7



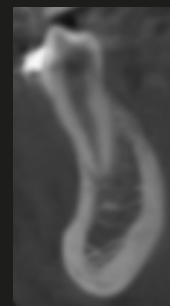DTE 4.6



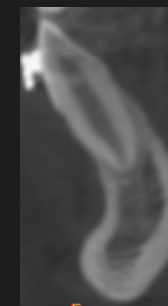
DTE 4.5



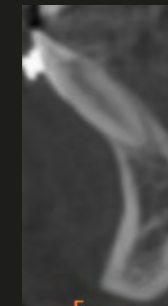
DTE 4.4



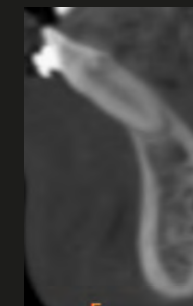DTE 4.3



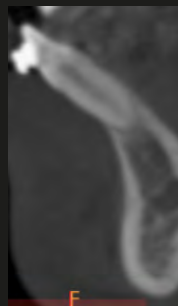
DTE 4.2



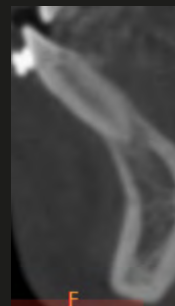
DTE 4.1



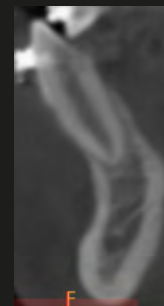
DTE 3.1



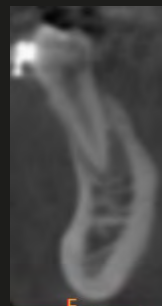
DTE 3.2



DTE 3.3



DTE 3.4



DTE 3.5



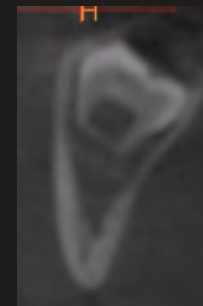DTE 3.6



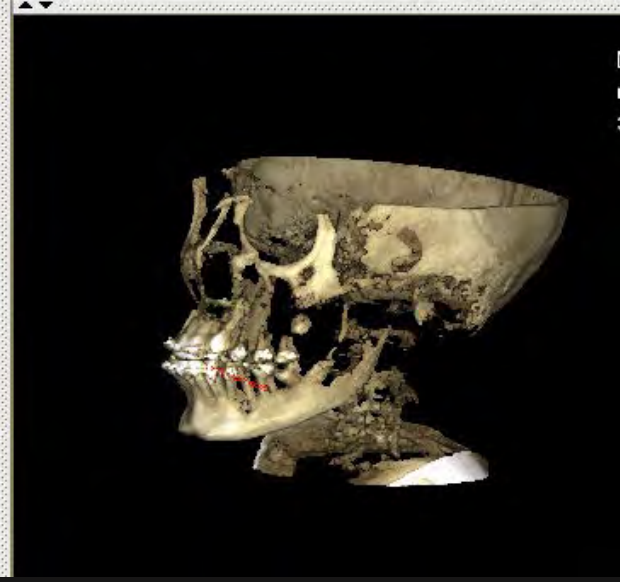
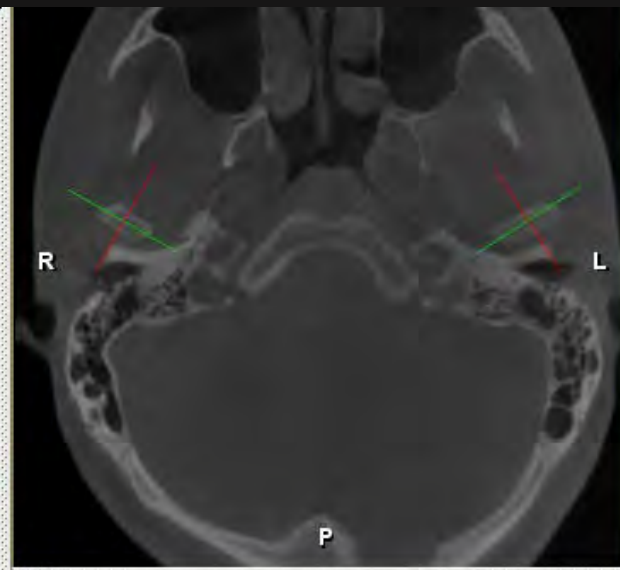
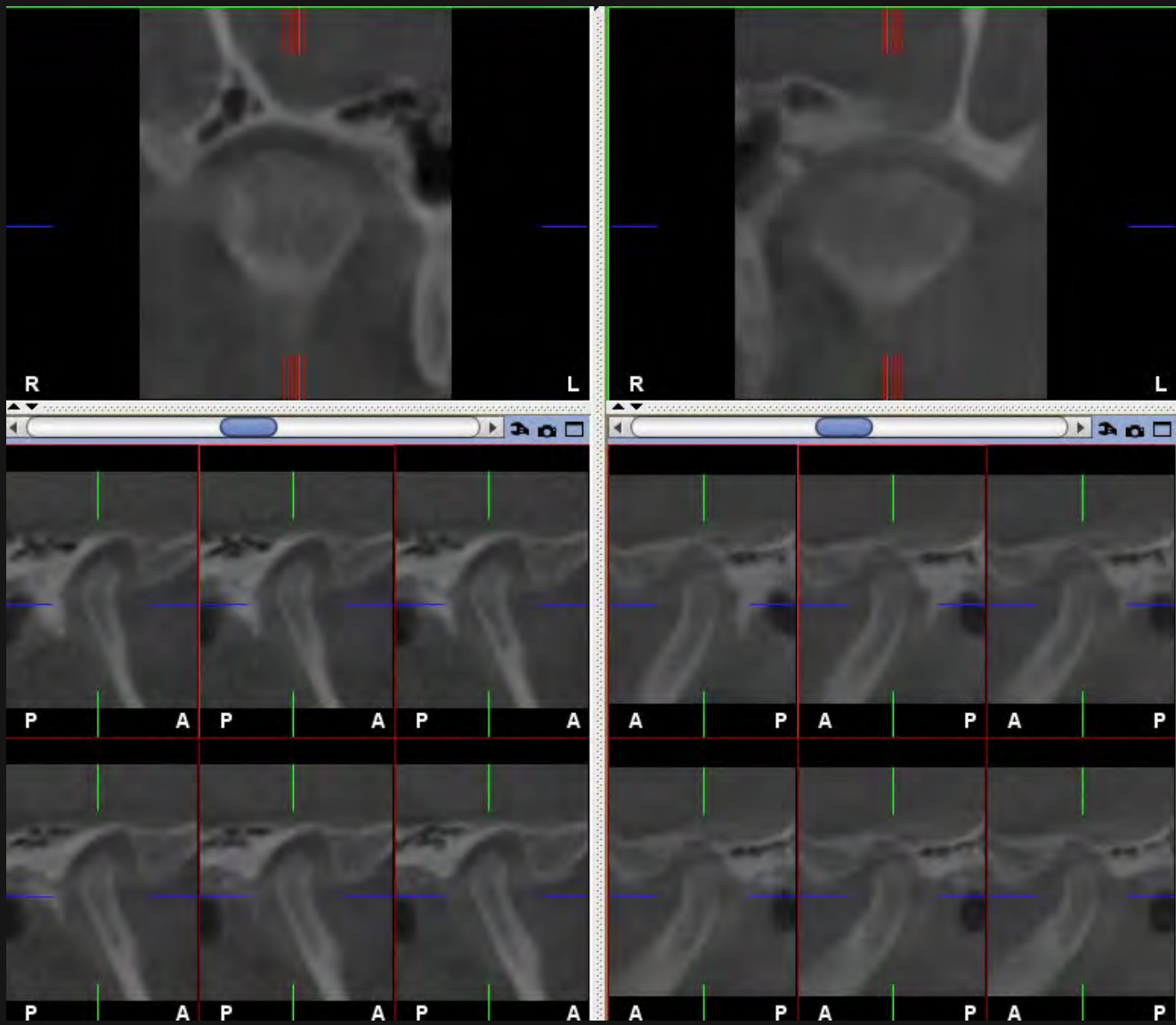
DTE 3.7



DTE 3.8

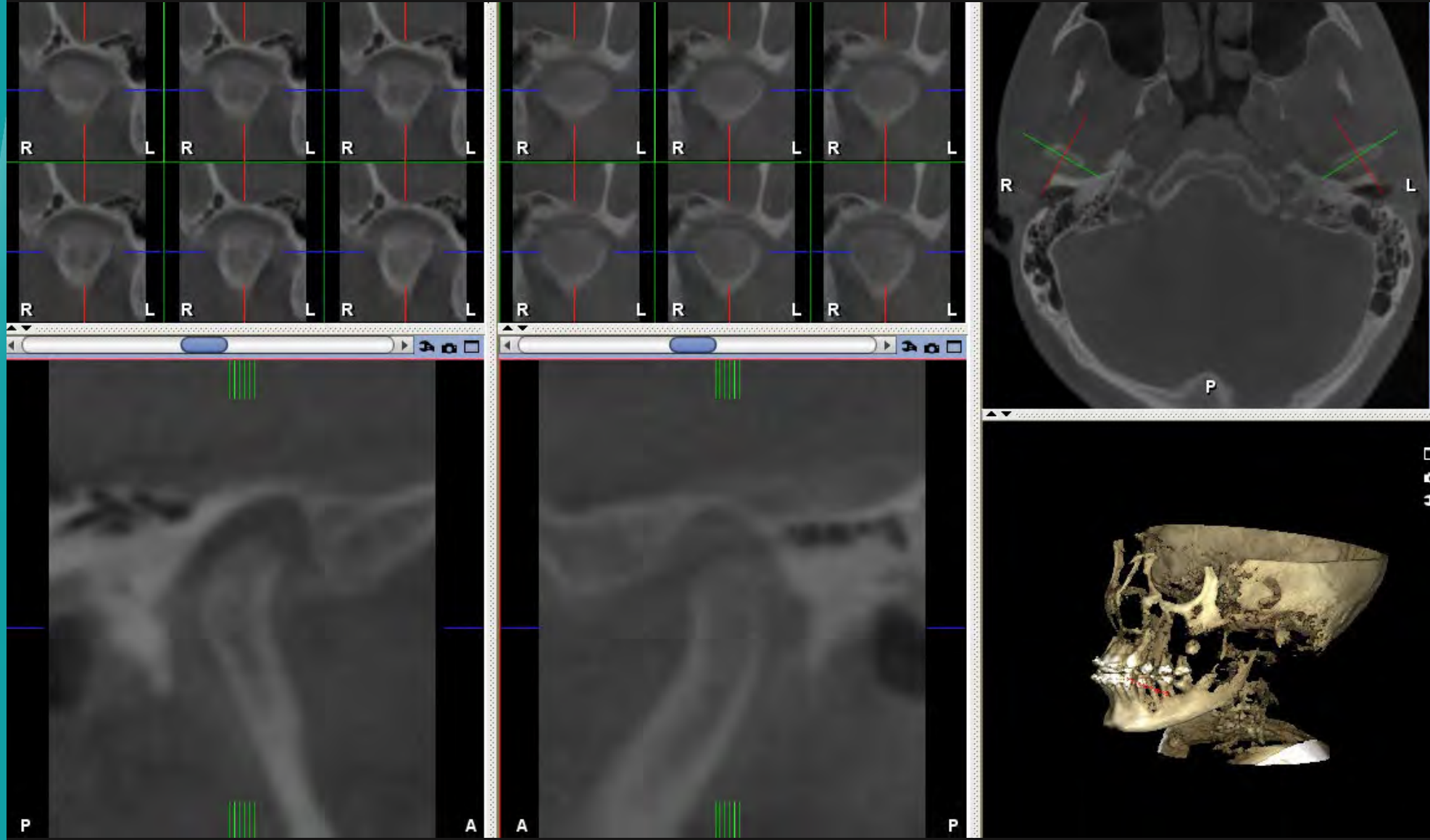


Estudio de la ATM Cortes Sagitales



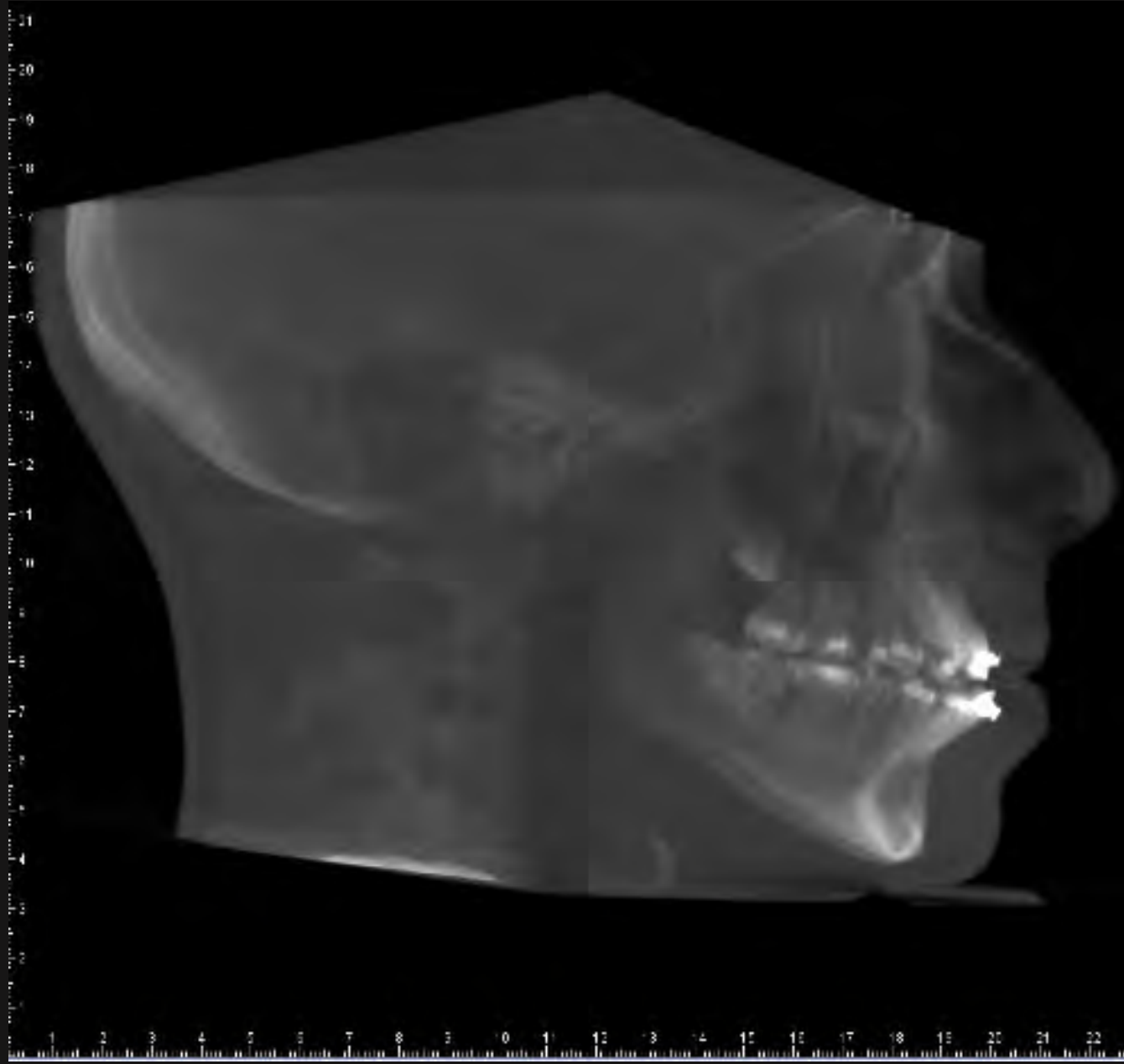
ICF3D

Estudio de la ATM Cortes Coroneles



ICF3D

Telerradiografía de Perfil



Paciente: Martin Ramos Vellela

Fecha: 25-07-2021

Edad Dental: 14A 9M Sexo: Hombre

Análisis de Ricketts

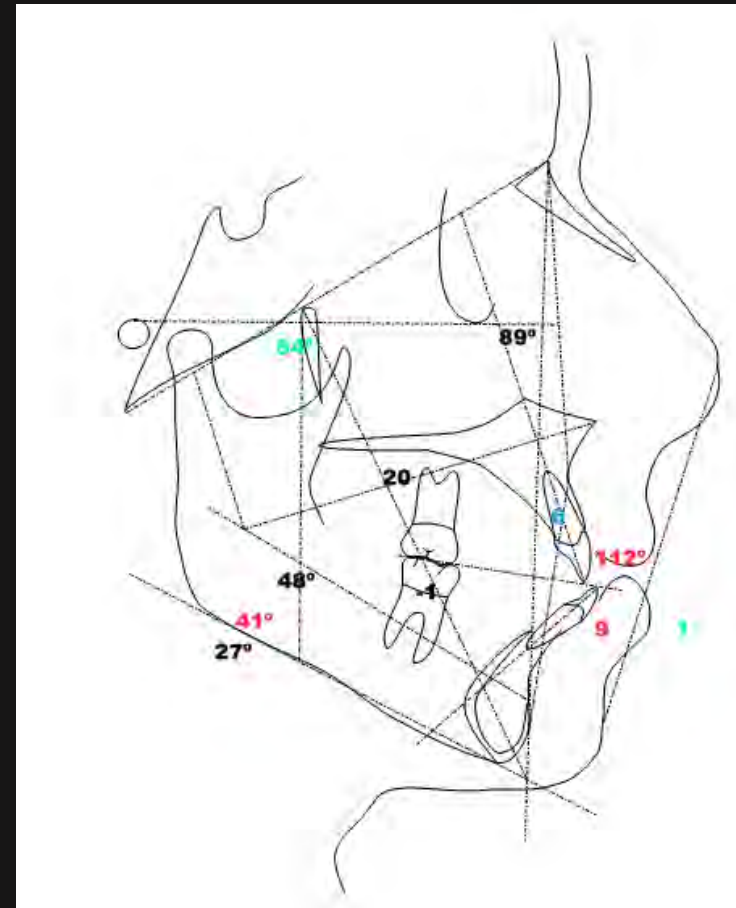
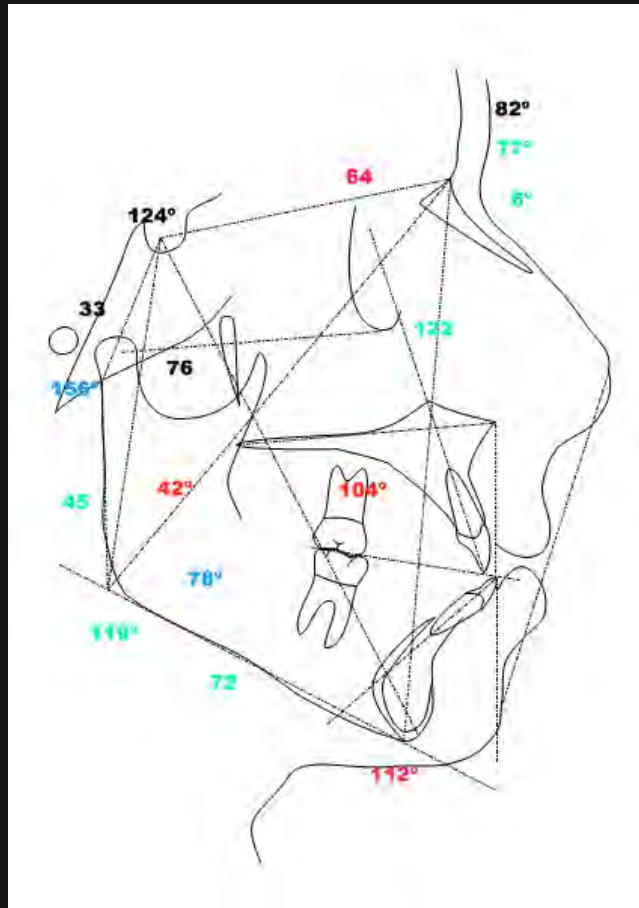
Cefalometría Lateral

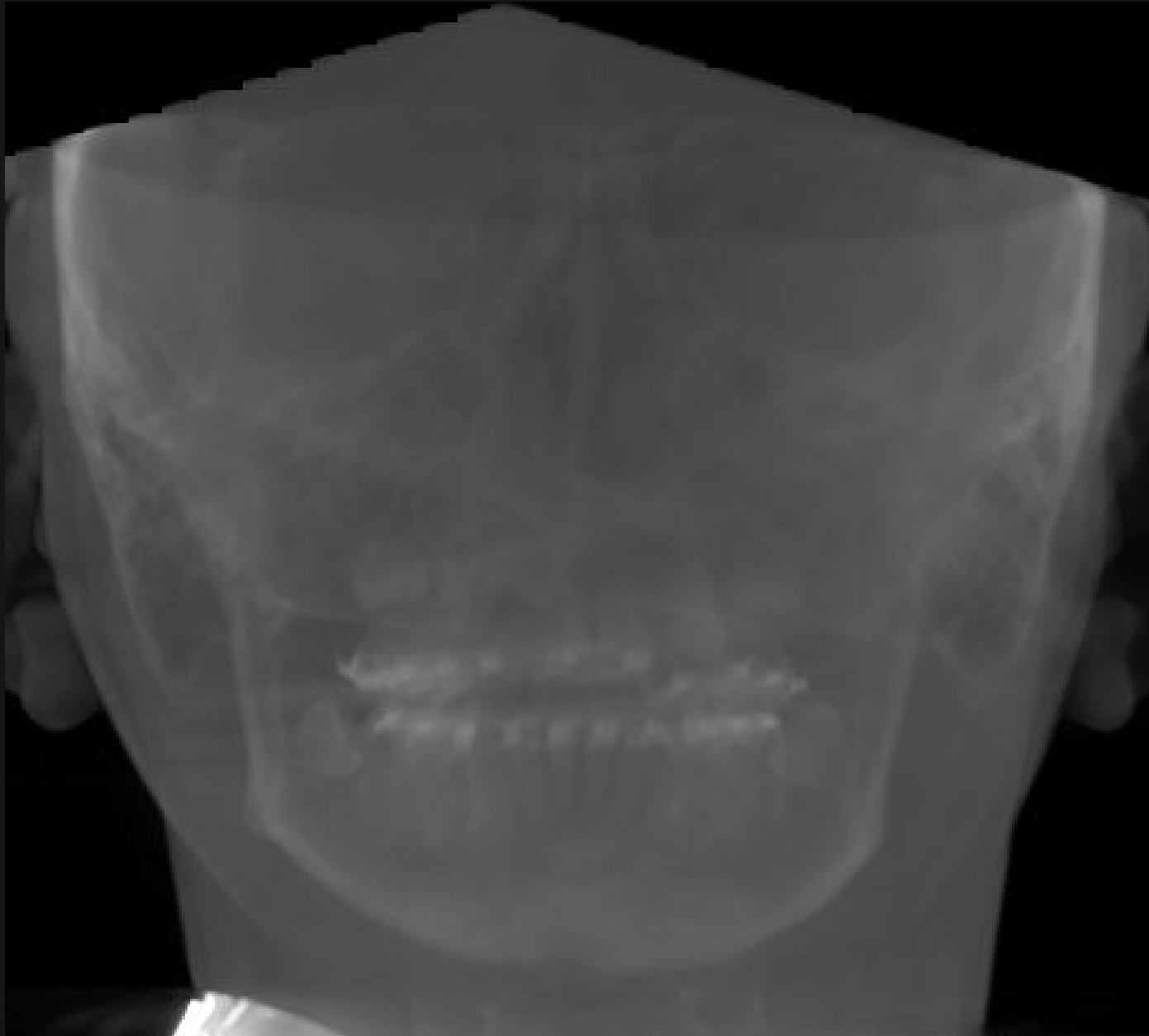
Pretratamiento

Vert: 0,1 MesoFacial.



ICF3D

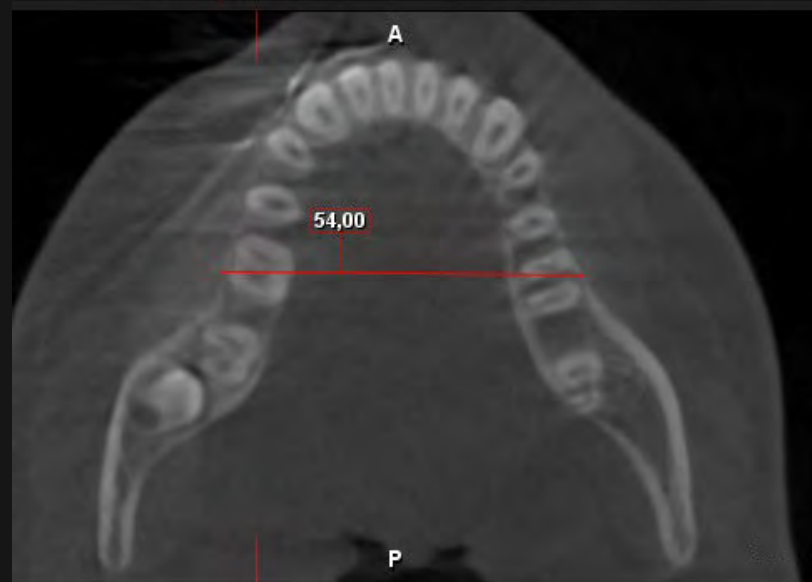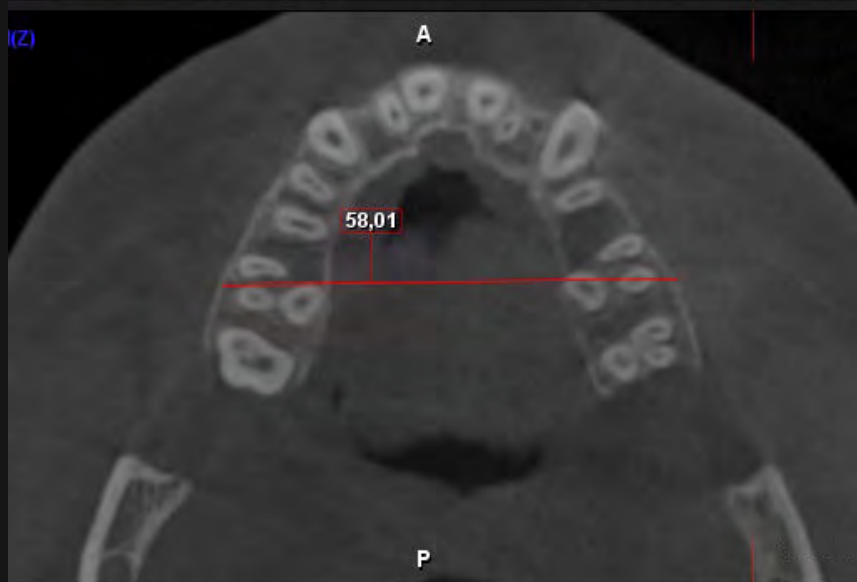

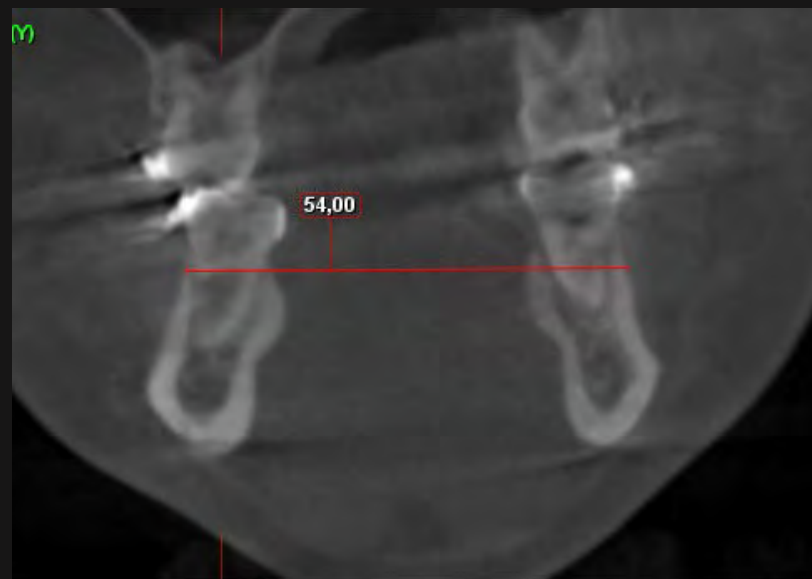
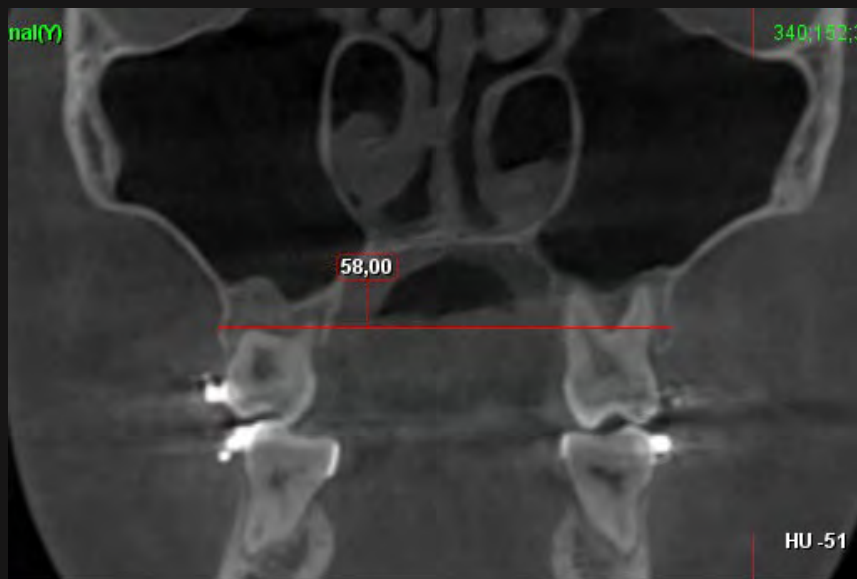

ICF3D

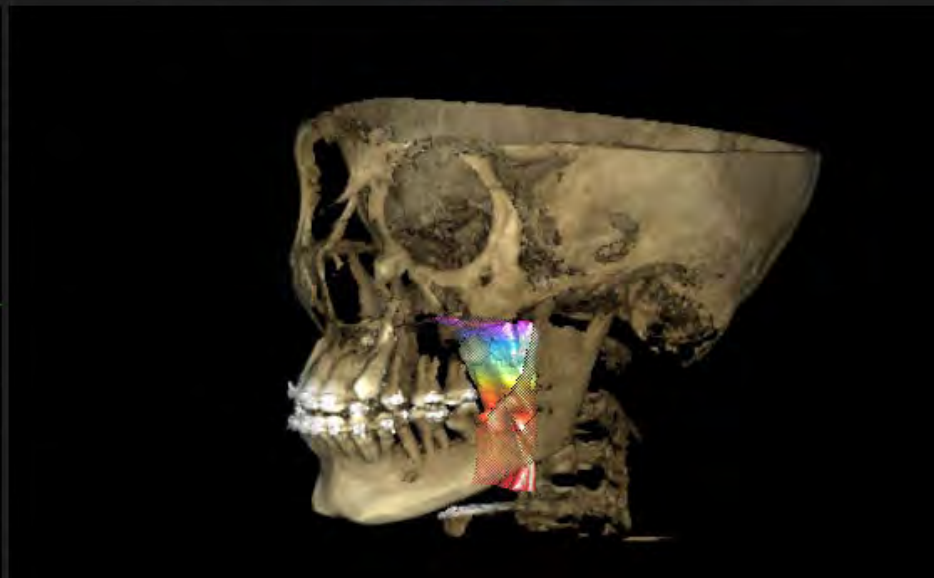
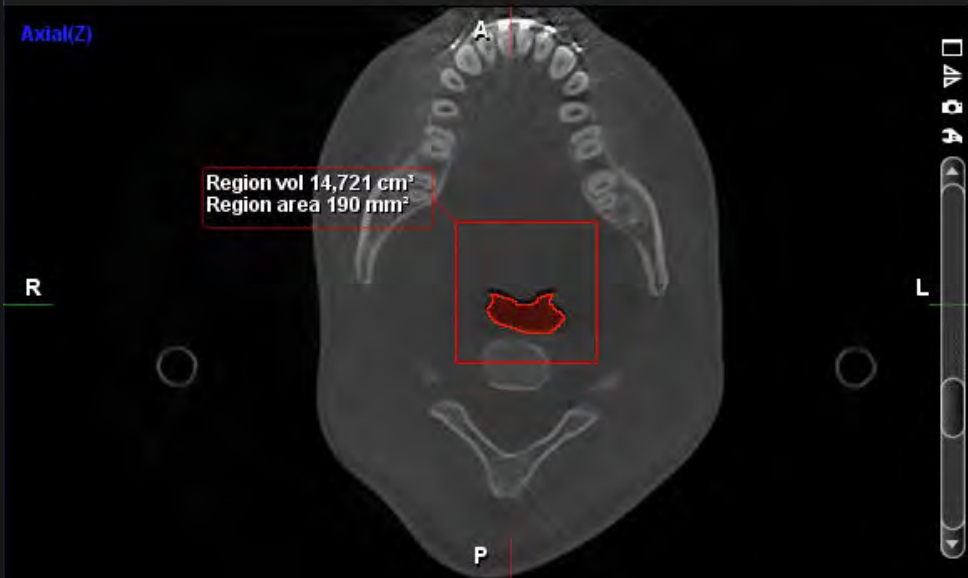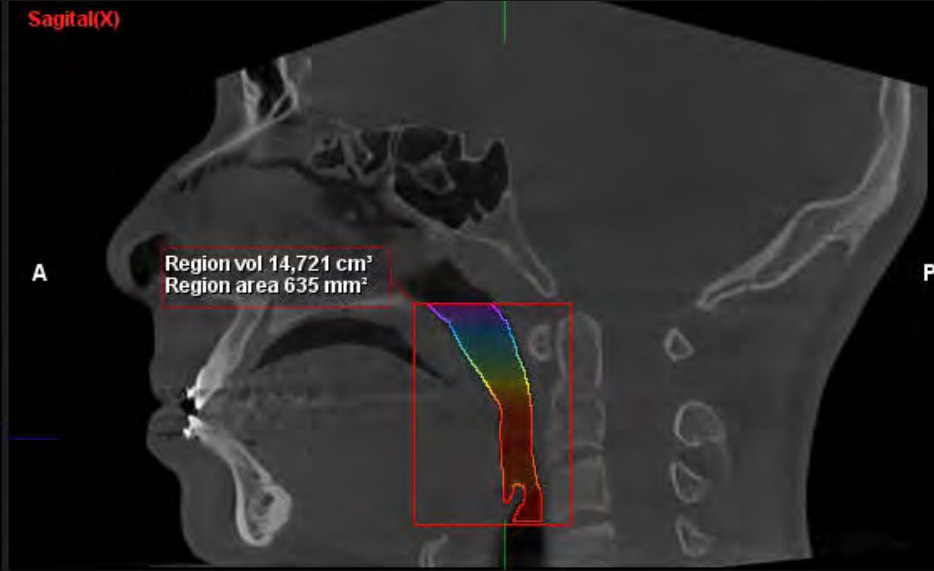
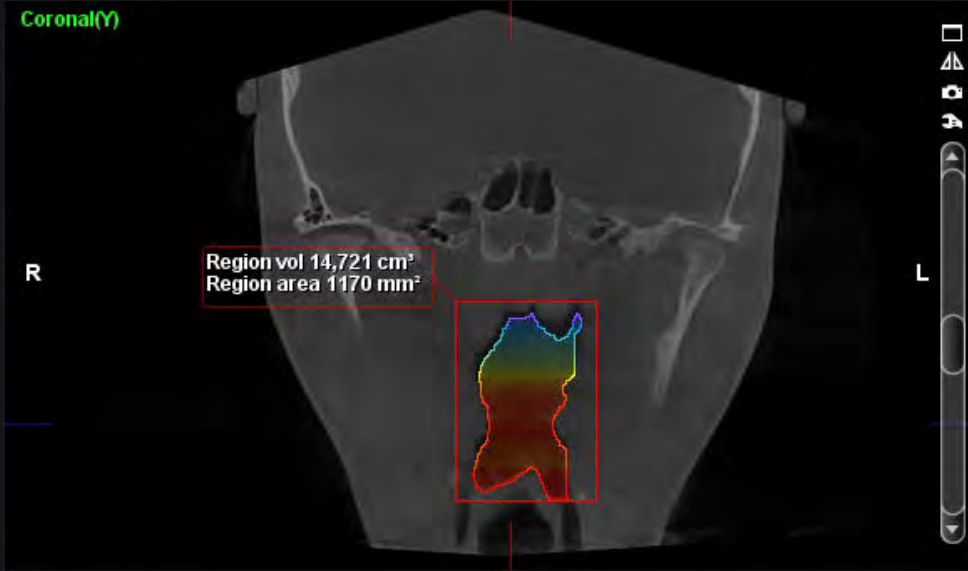


ICF3D



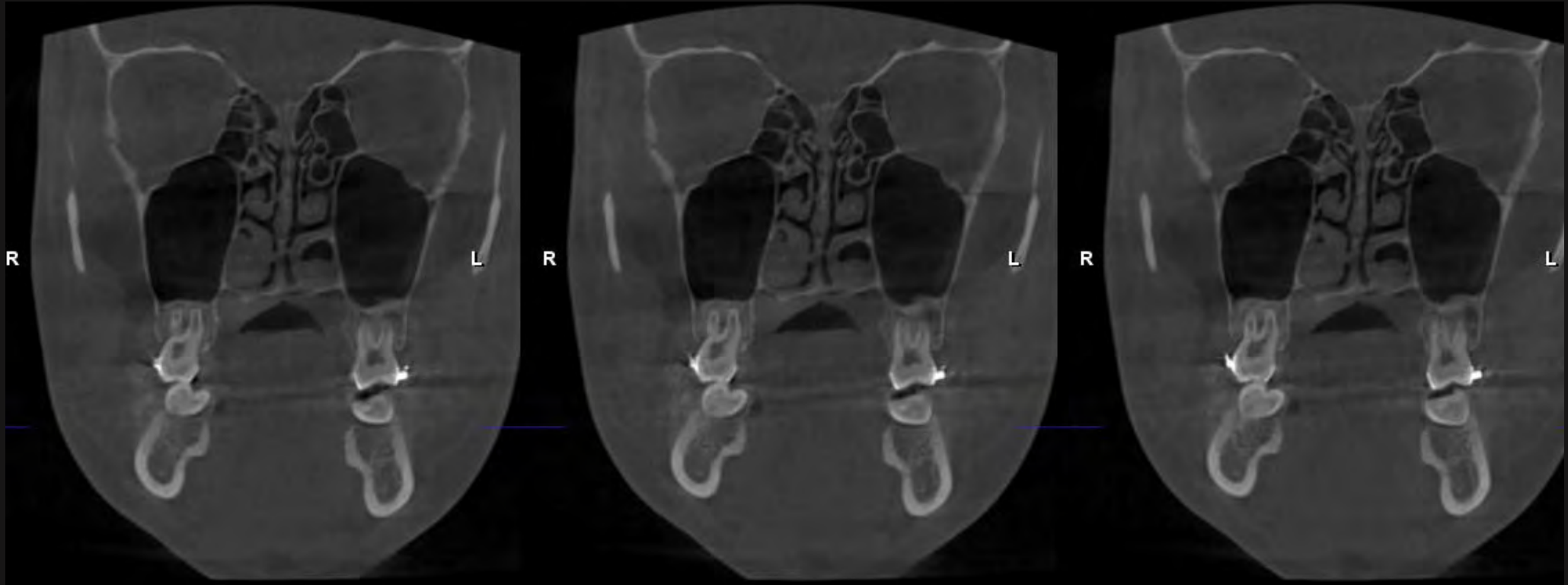

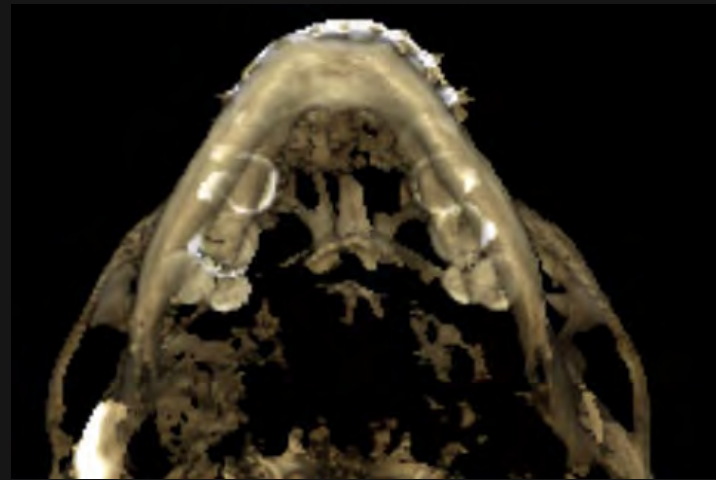
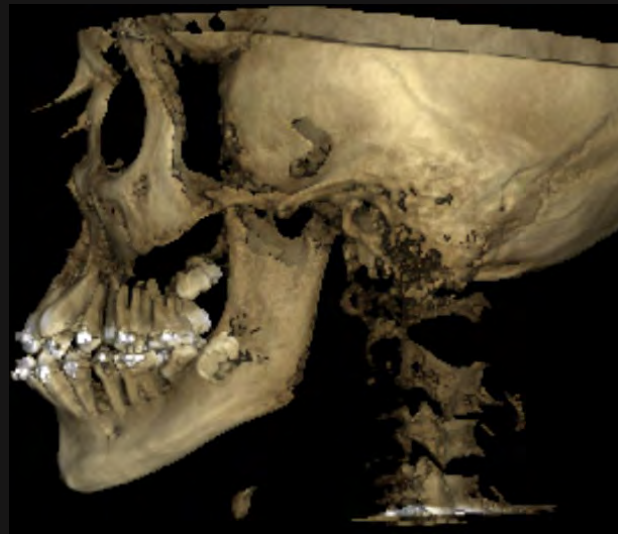
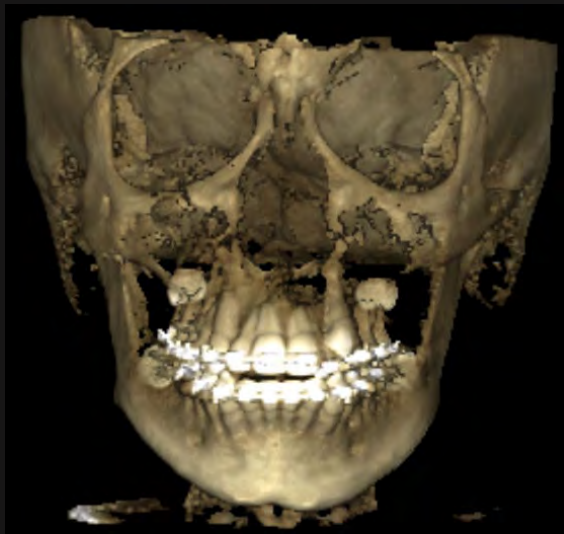
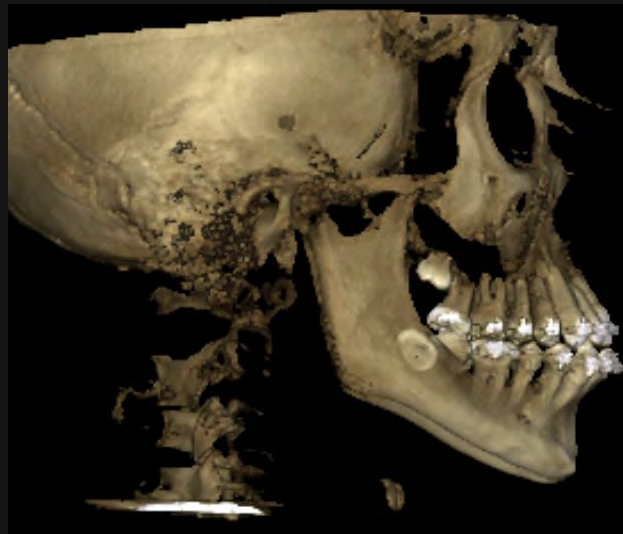ICF3D





ICF3D





ICF3D