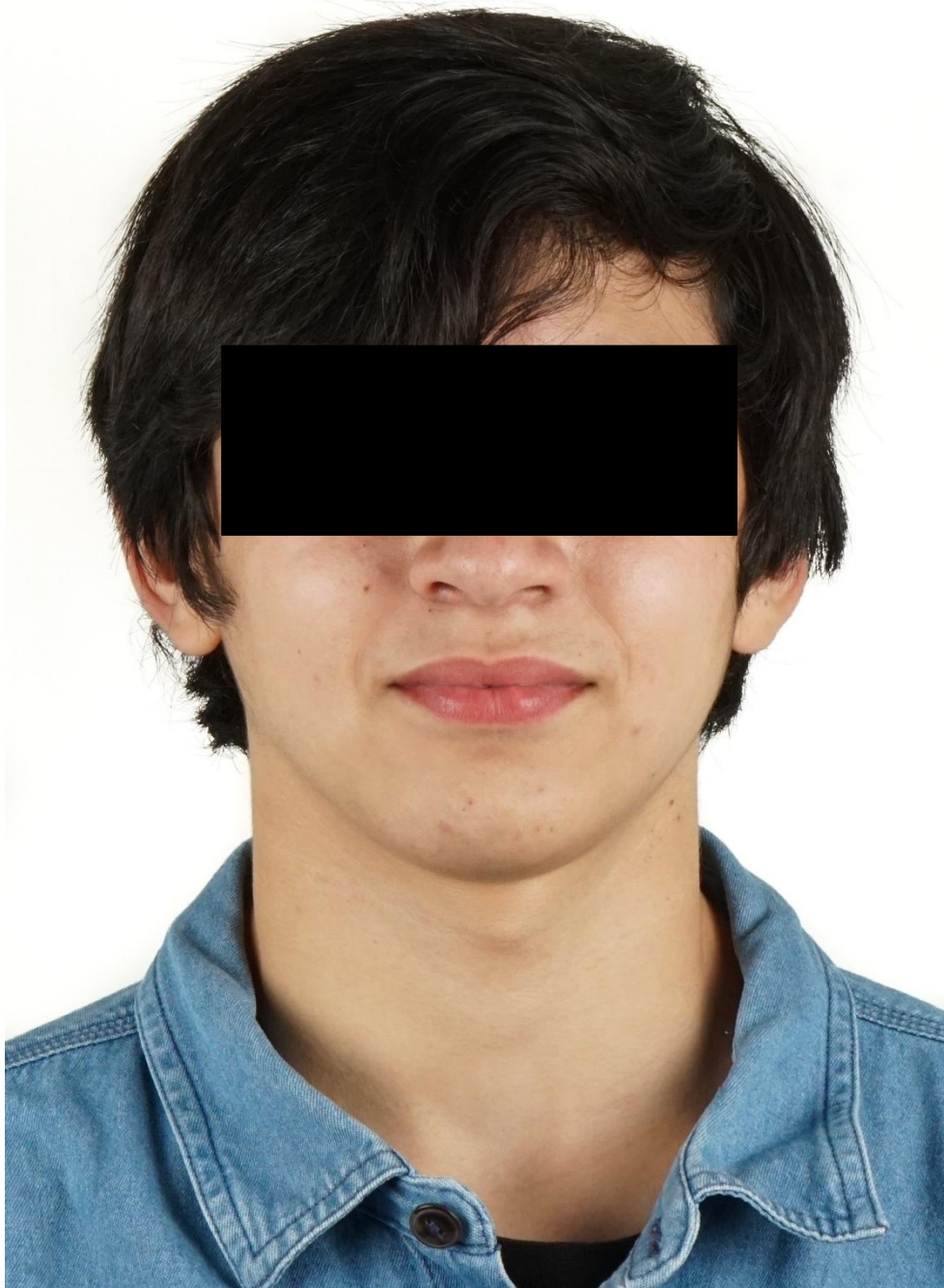


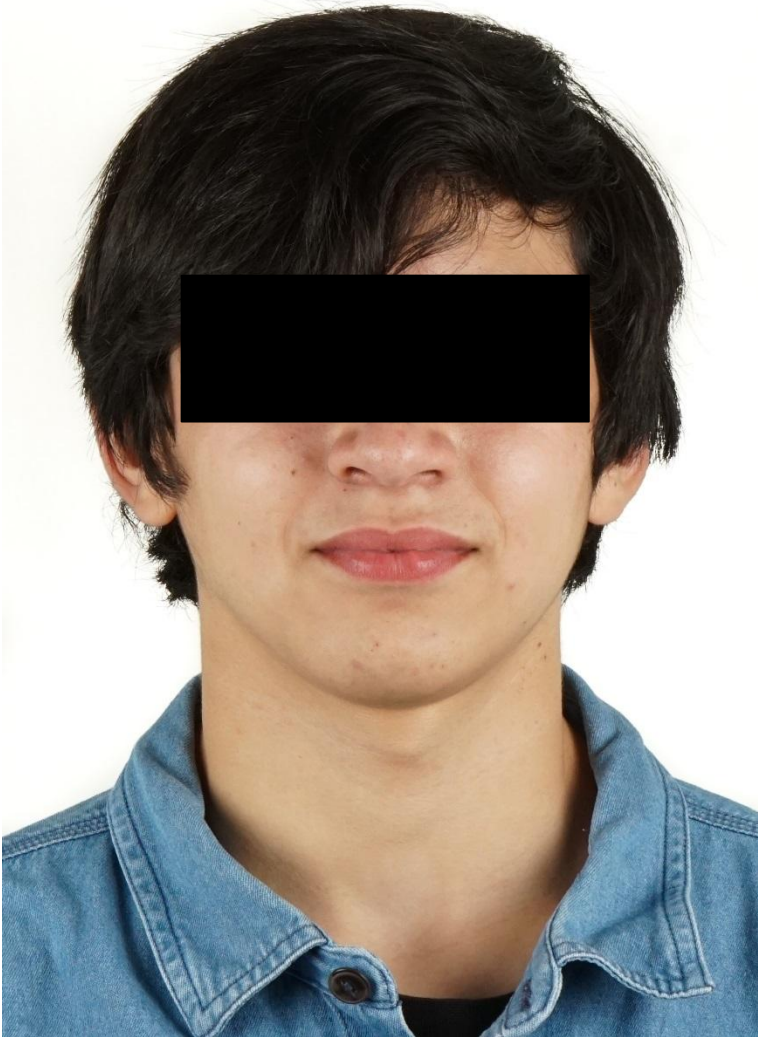
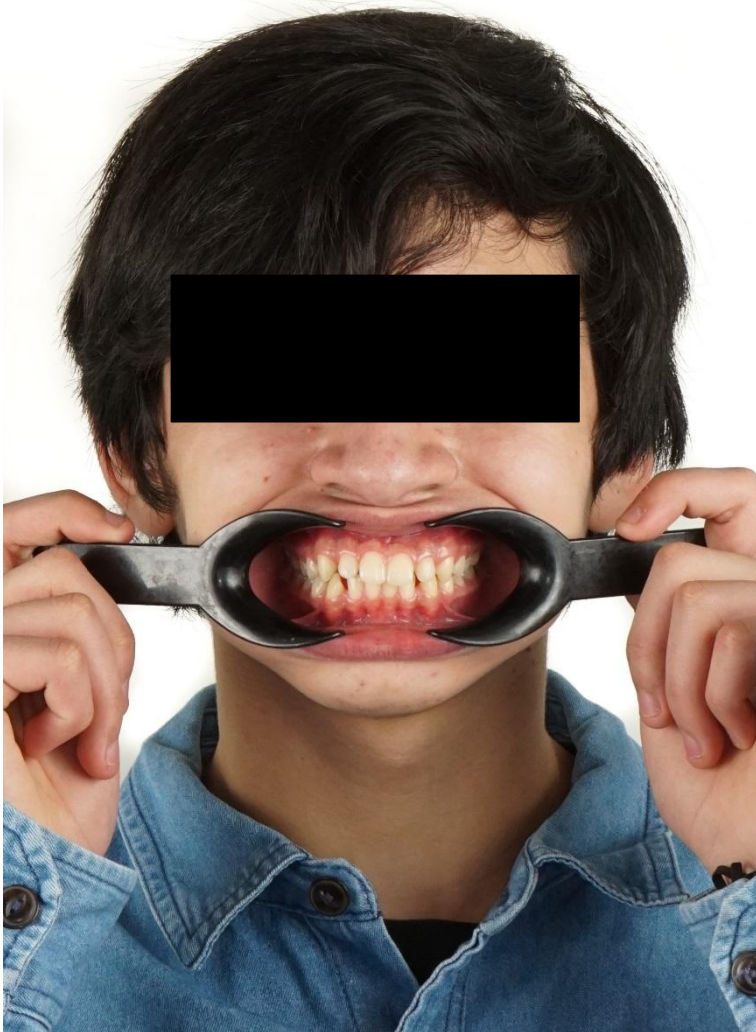Paciente: Matías Cisneros Del Fierro  
Dra. Pamela Agurto

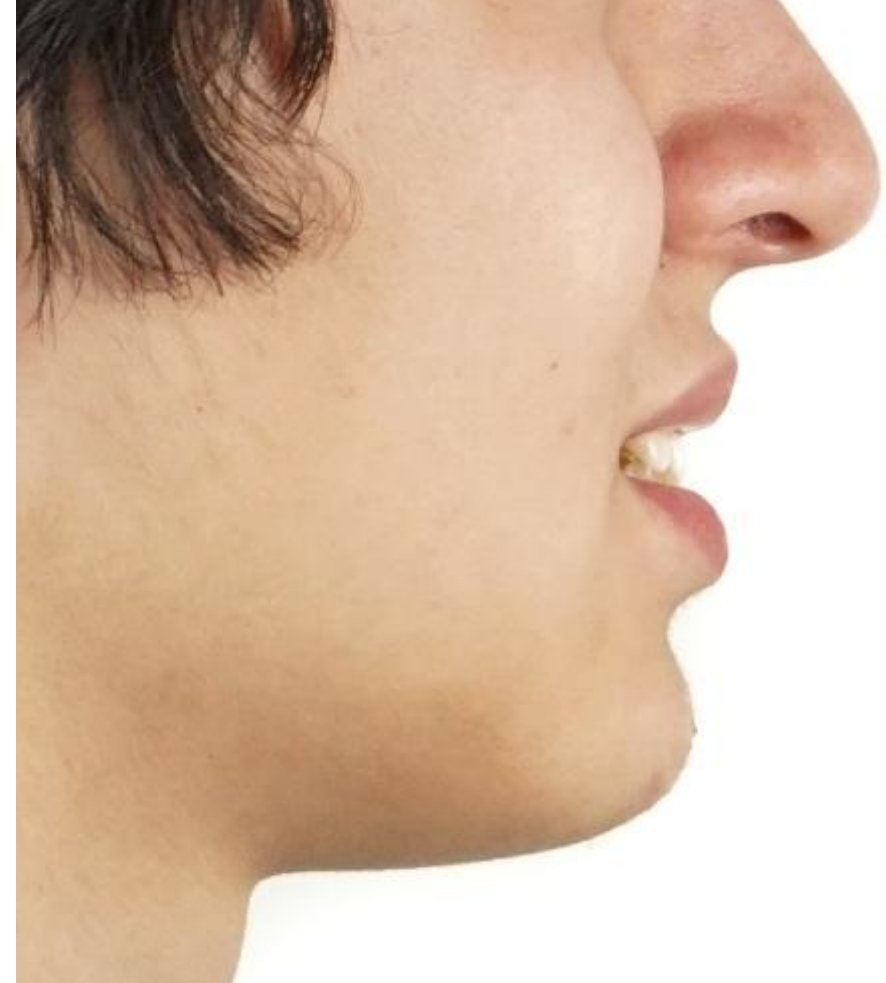
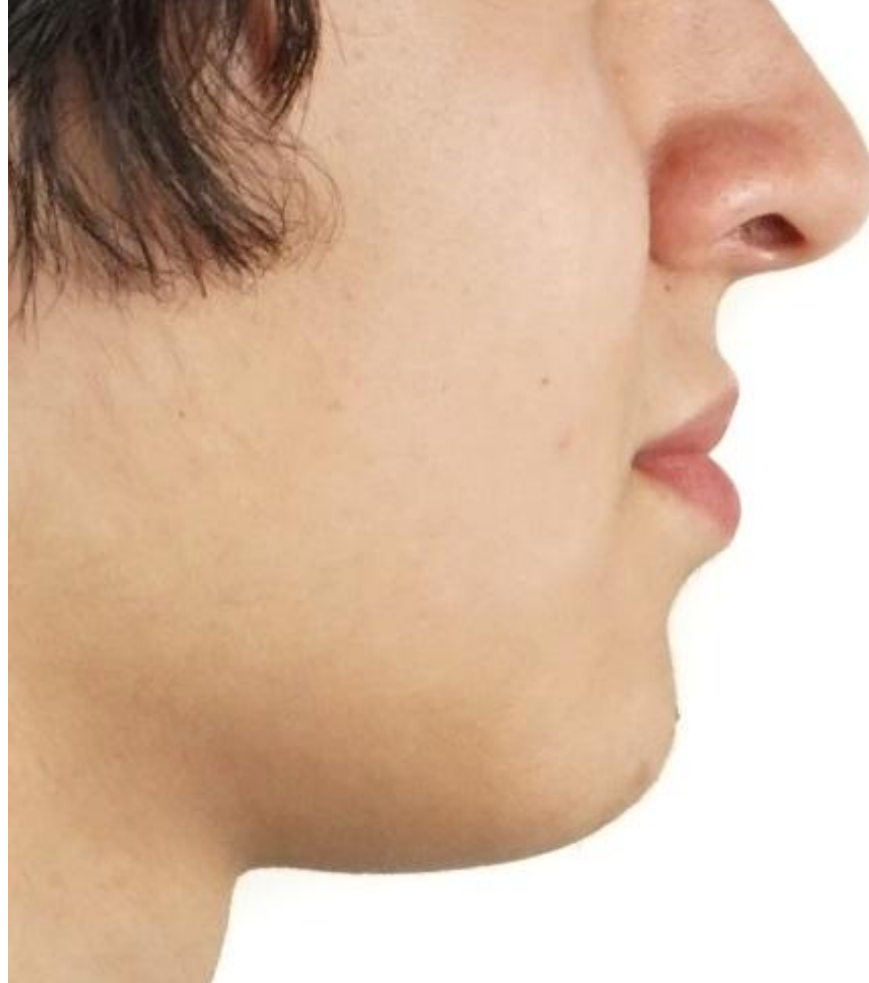


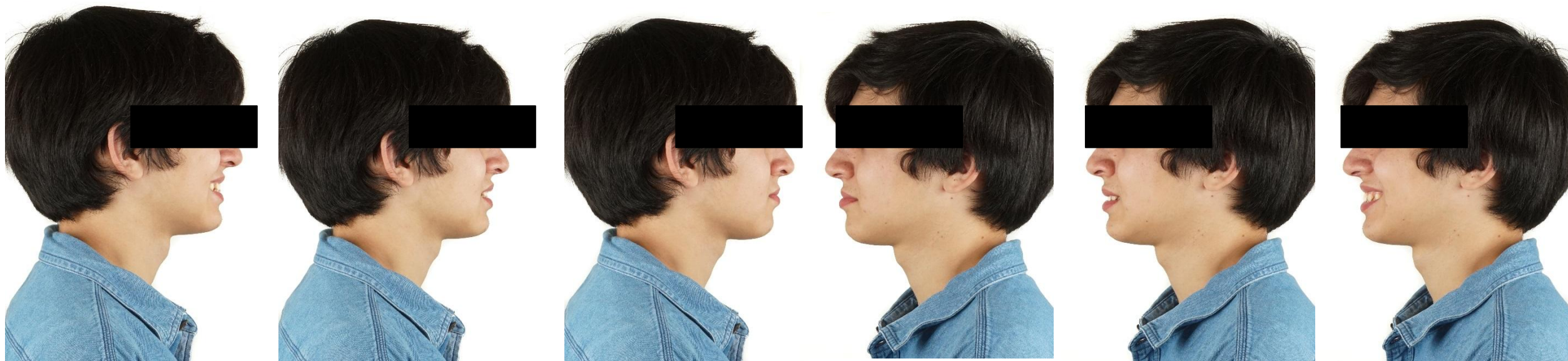## Información del caso

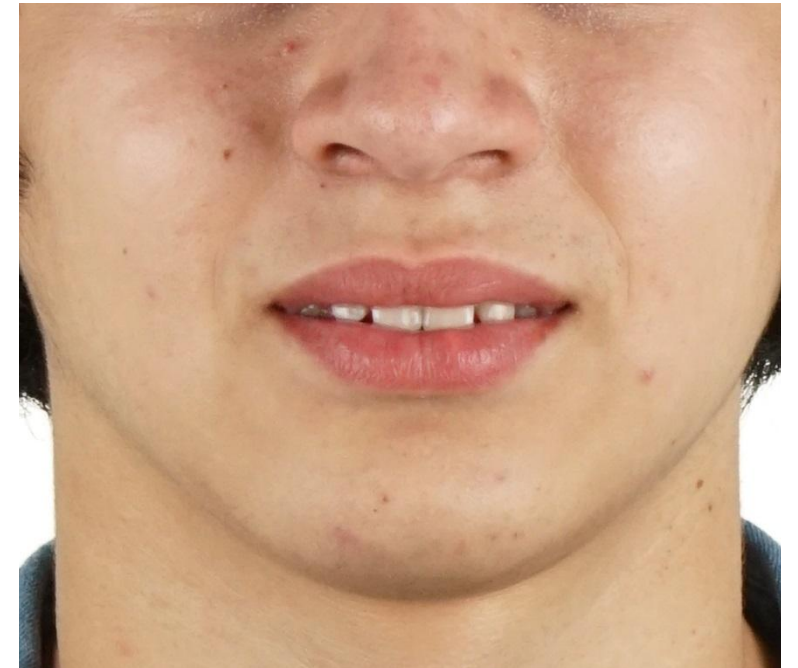
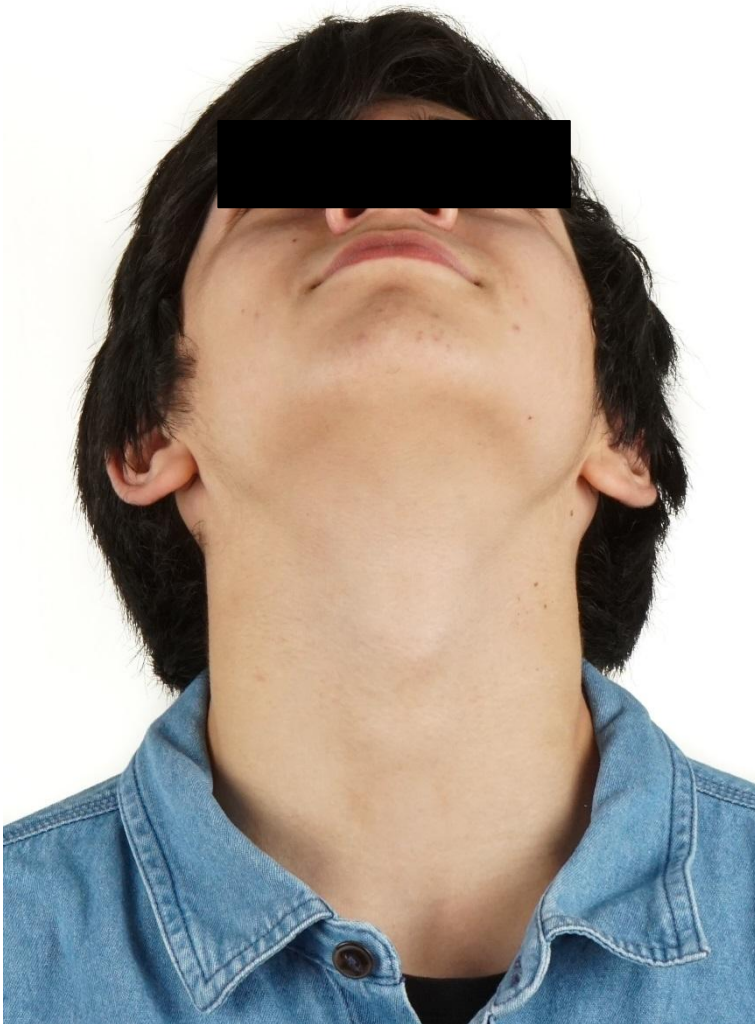Matías Cisneros Del Fierro  
31 de Mayo del 2007

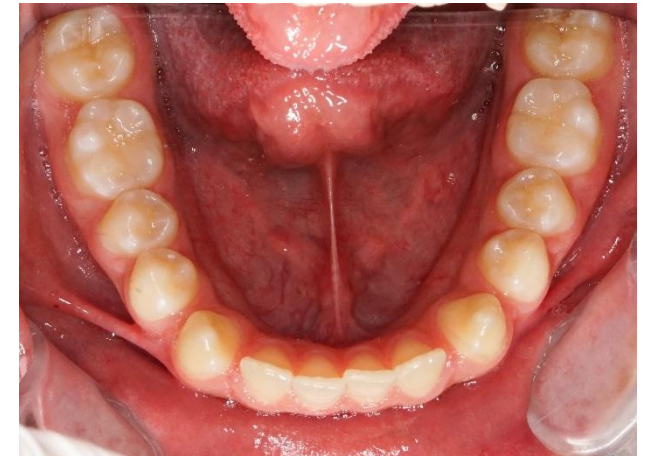
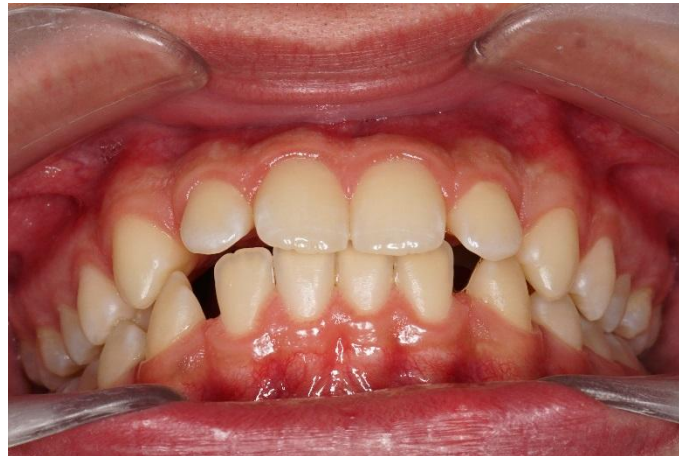
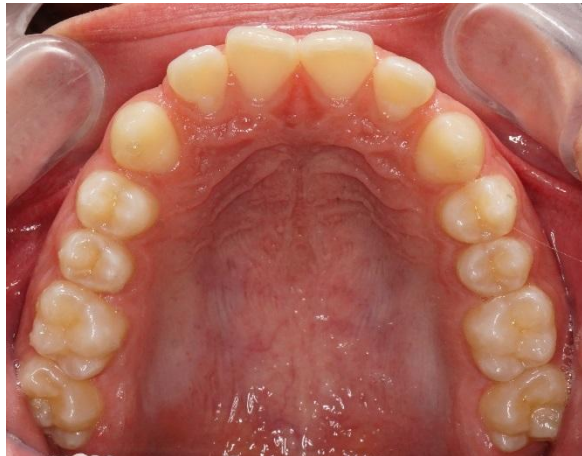
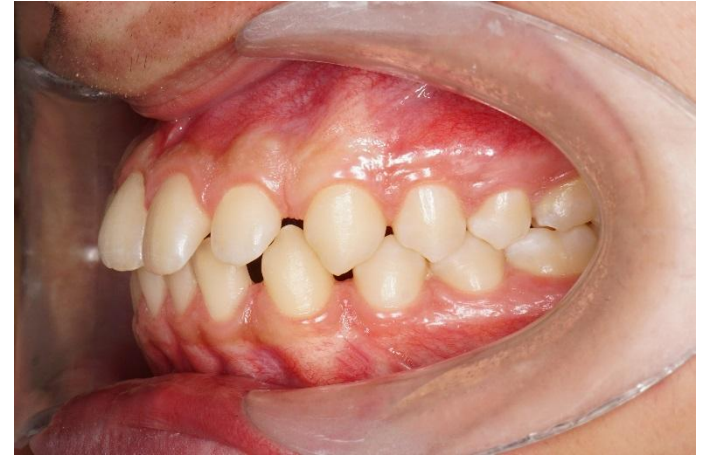
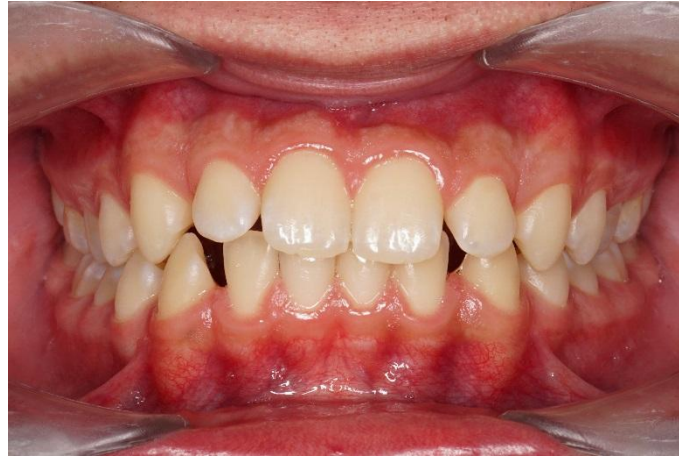
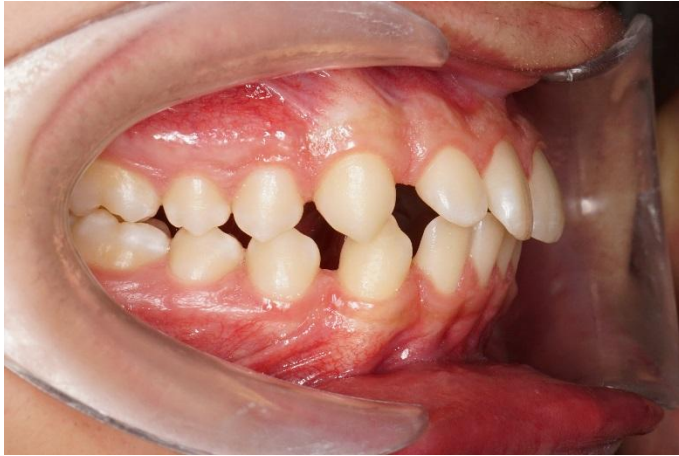




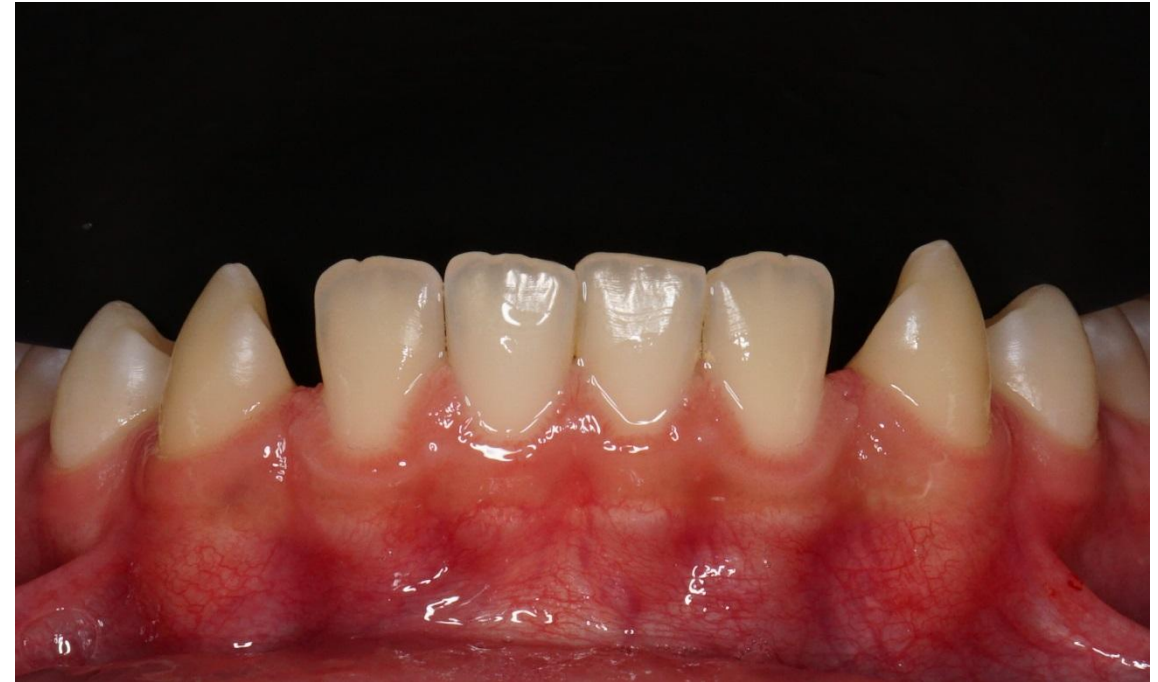
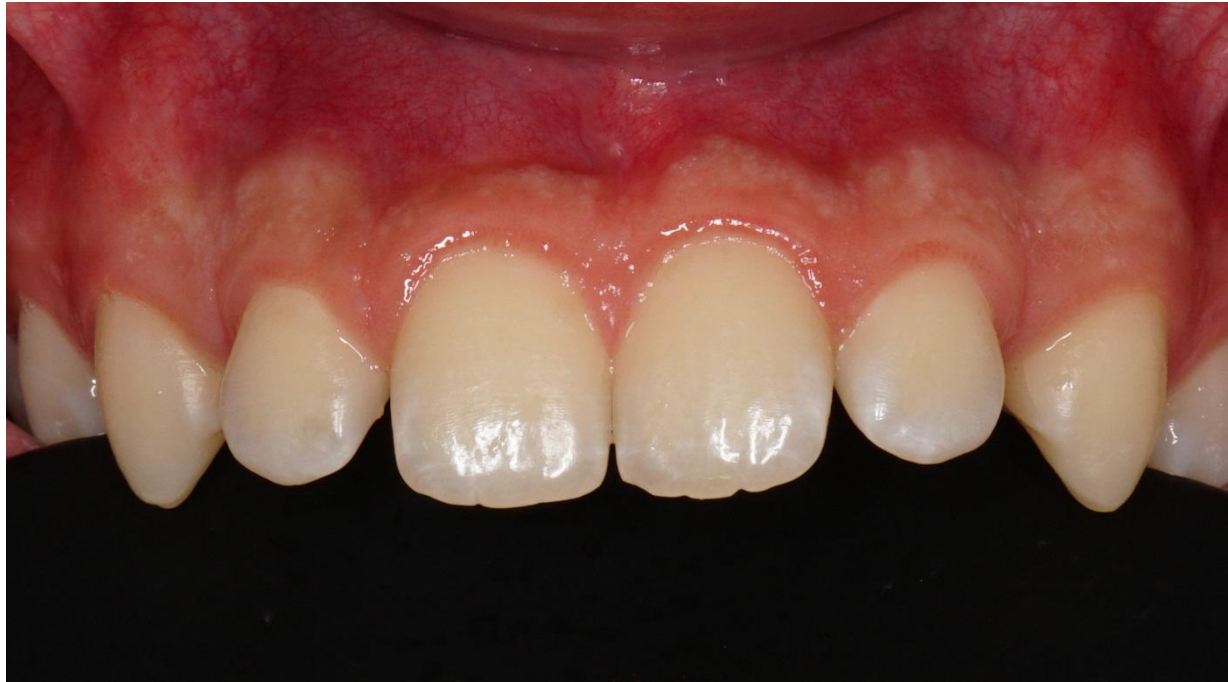

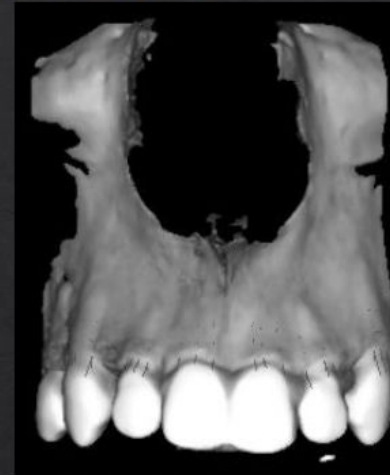
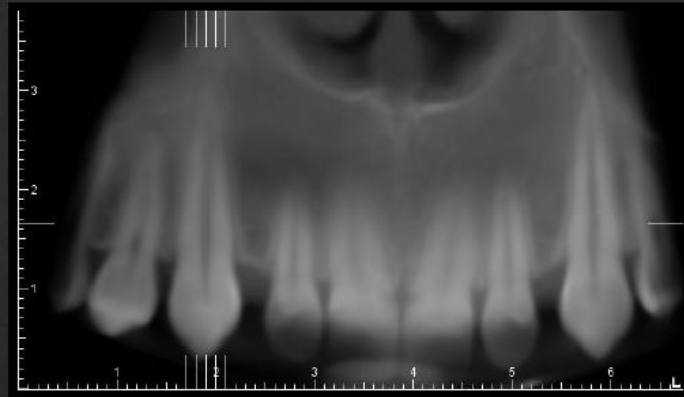




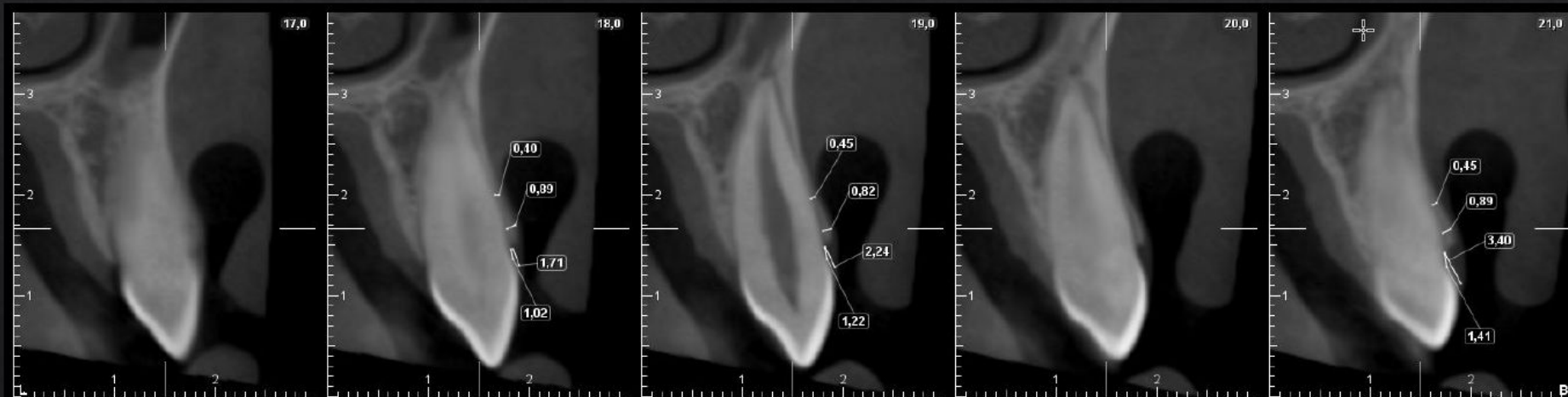## Estudio Periodontal

- ◇ En cada diente se realizan medidas en corte distal, medio y mesial.
- ◇ En dientes superiores e inferiores las medidas en orden coronal a apical corresponden a:
  - ◇ Distancia cresta ósea – LAC
  - ◇ Distancia cresta ósea – encía marginal
  - ◇ Grosor cortical ósea a 3 mm del LAC
  - ◇ Grosor cortical ósea a 6 mm del LAC
- ◇ En ocasiones estas medidas no se pueden realizar debido a que no se observan reparos anatómicos solicitados.

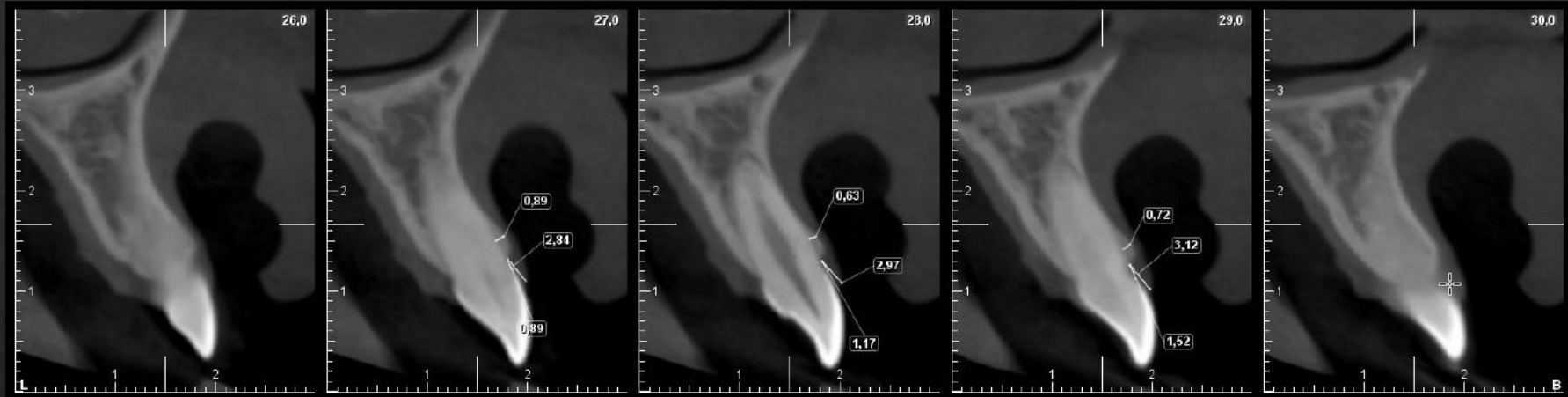
### CORTES EJE DENTARIO SUPERIOR



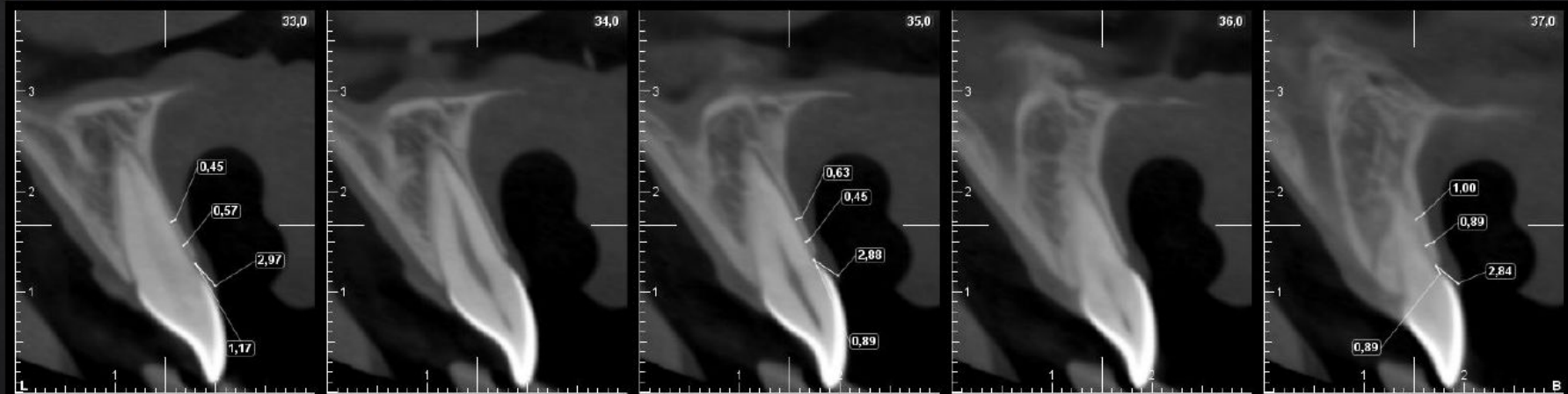
DIENTE 1.3



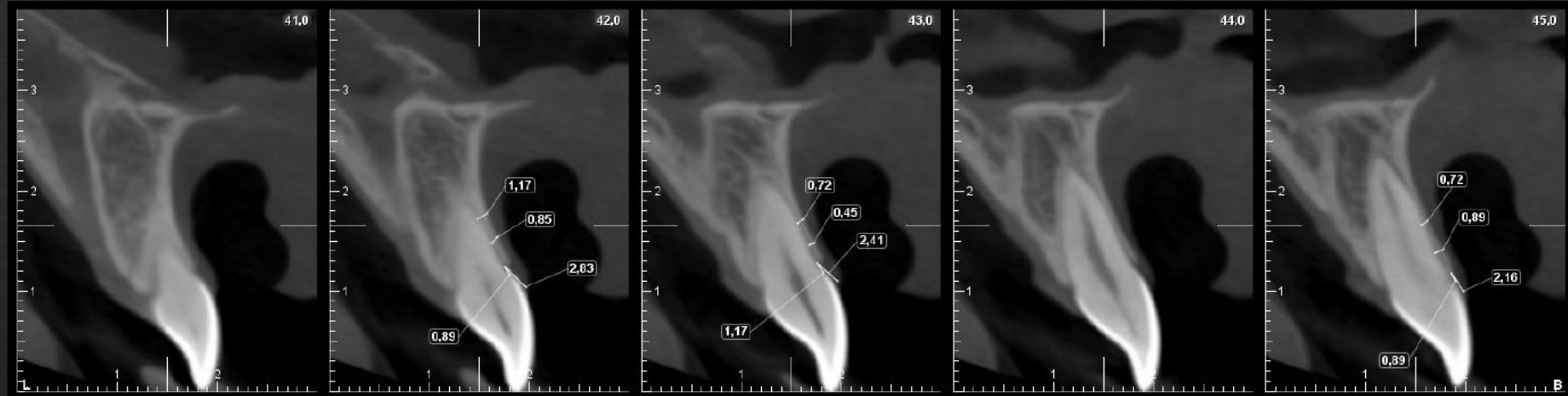
## DIENTE 1.2



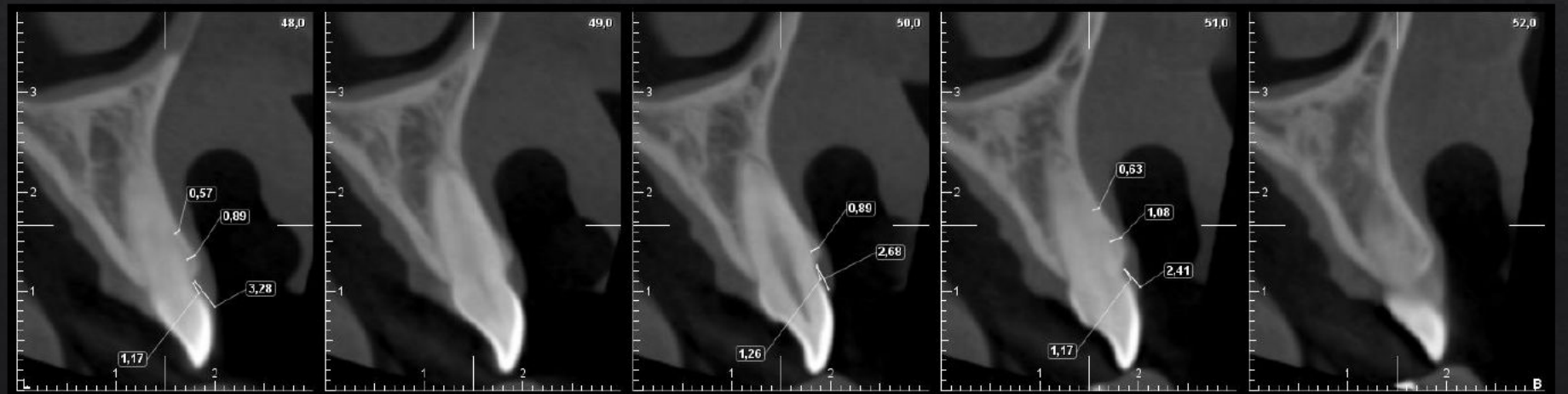
## DIENTE 1.1



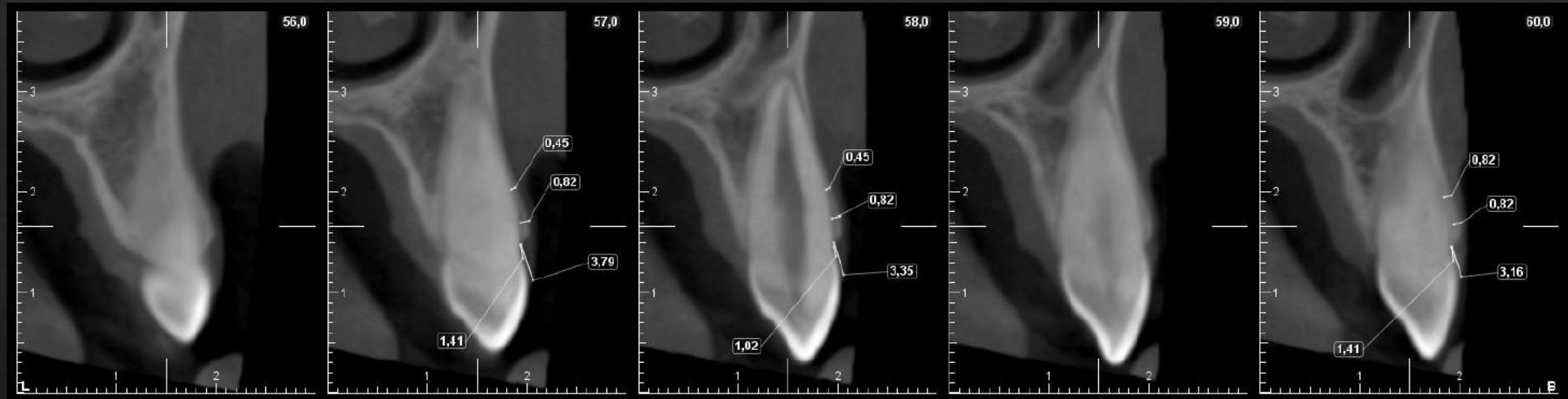
## DIENTE 2.1



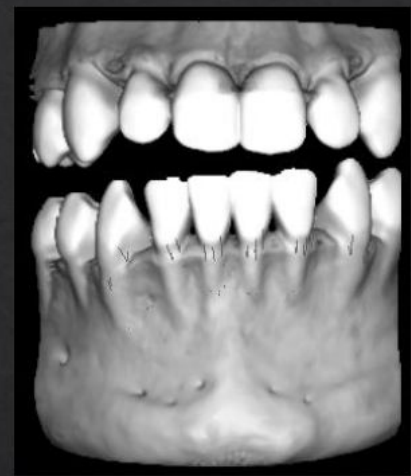
## DIENTE 2.2



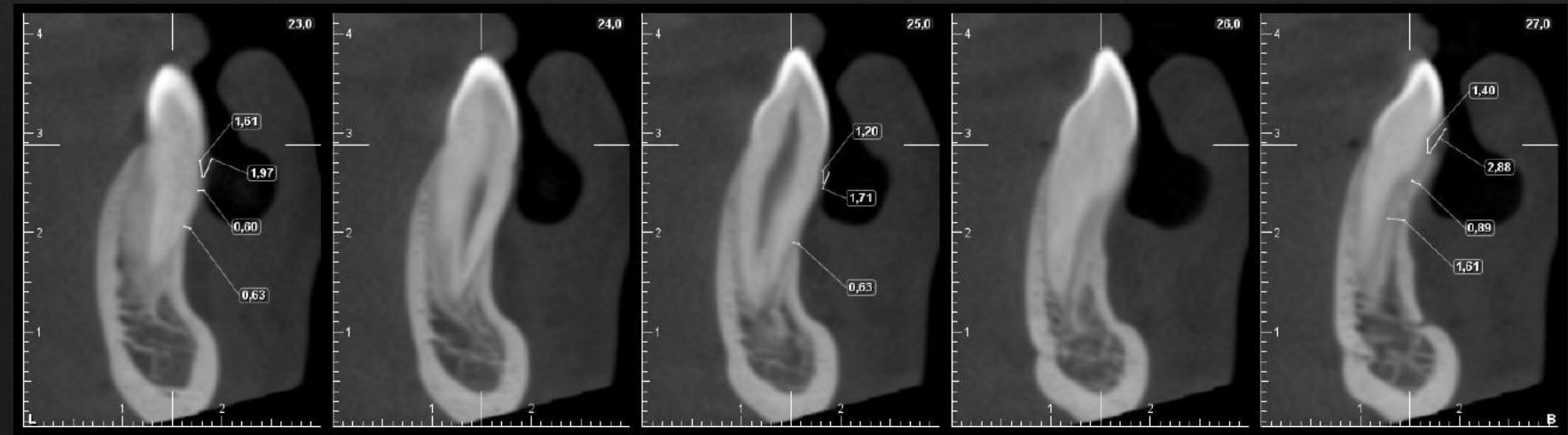
## DIENTE 2.3



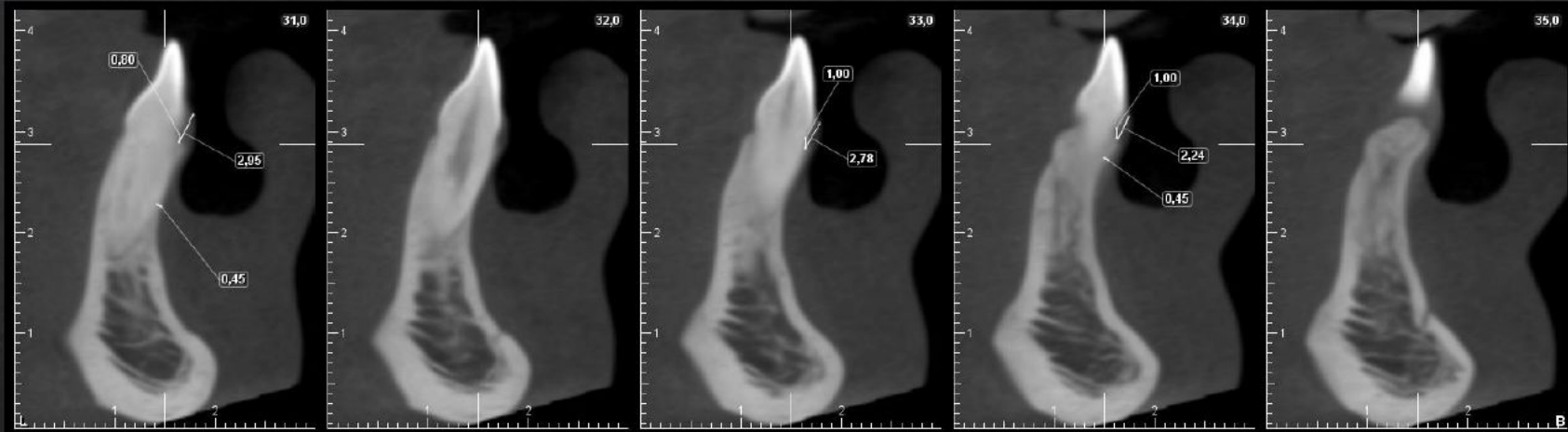
### CORTES EJE DENTARIO INFERIOR



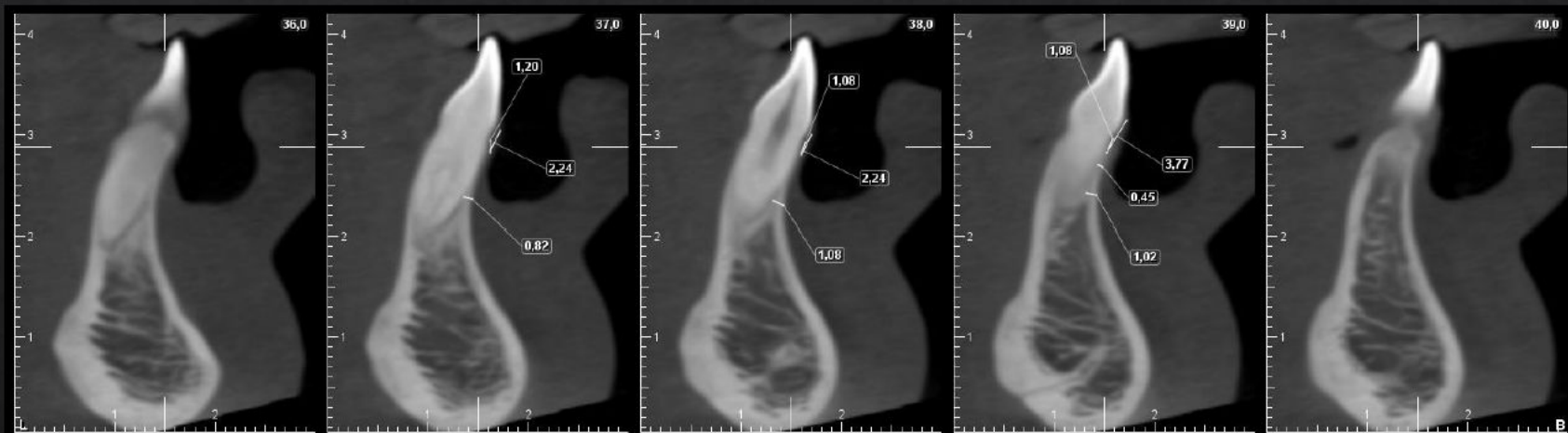
DIENTE 4.3



**DIENTE 4.2**

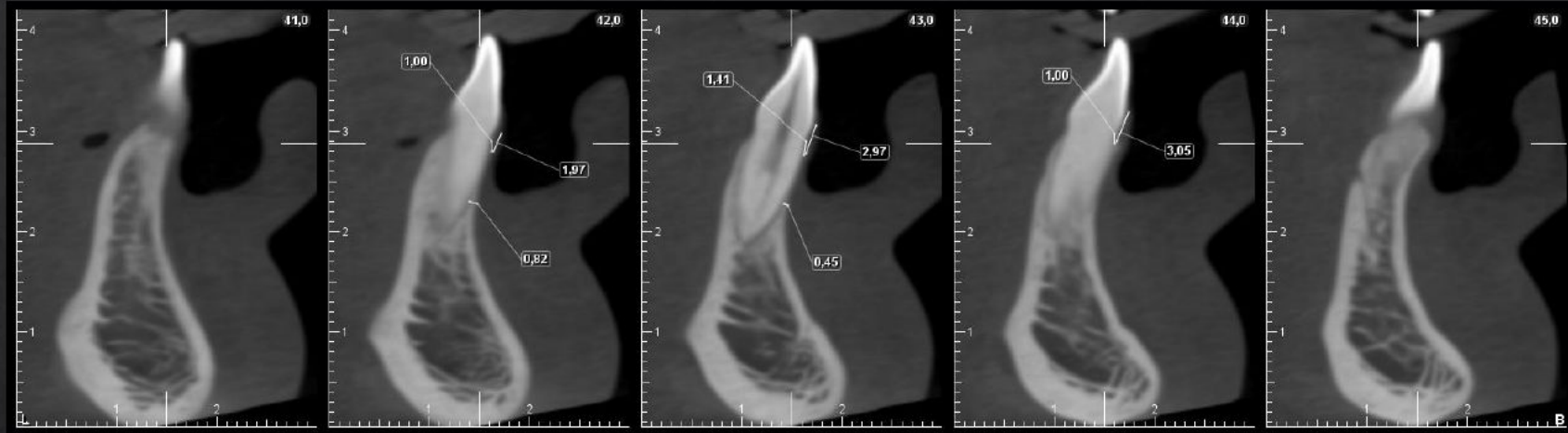


**DIENTE 4.1**

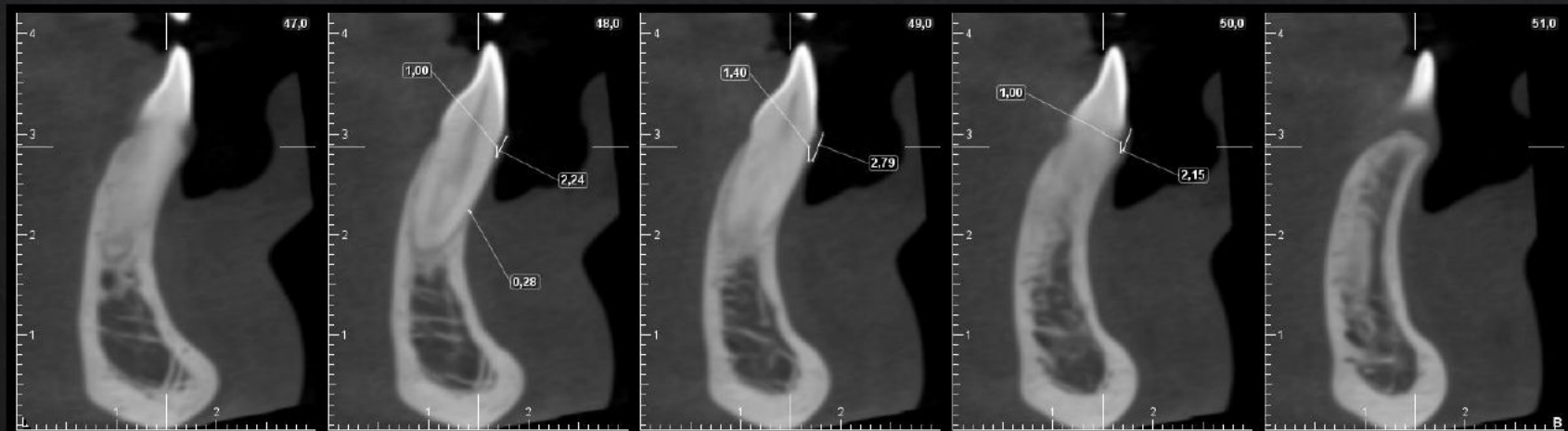




## DIENTE 3.1



## DIENTE 3.2



### DIENTE 4.3

