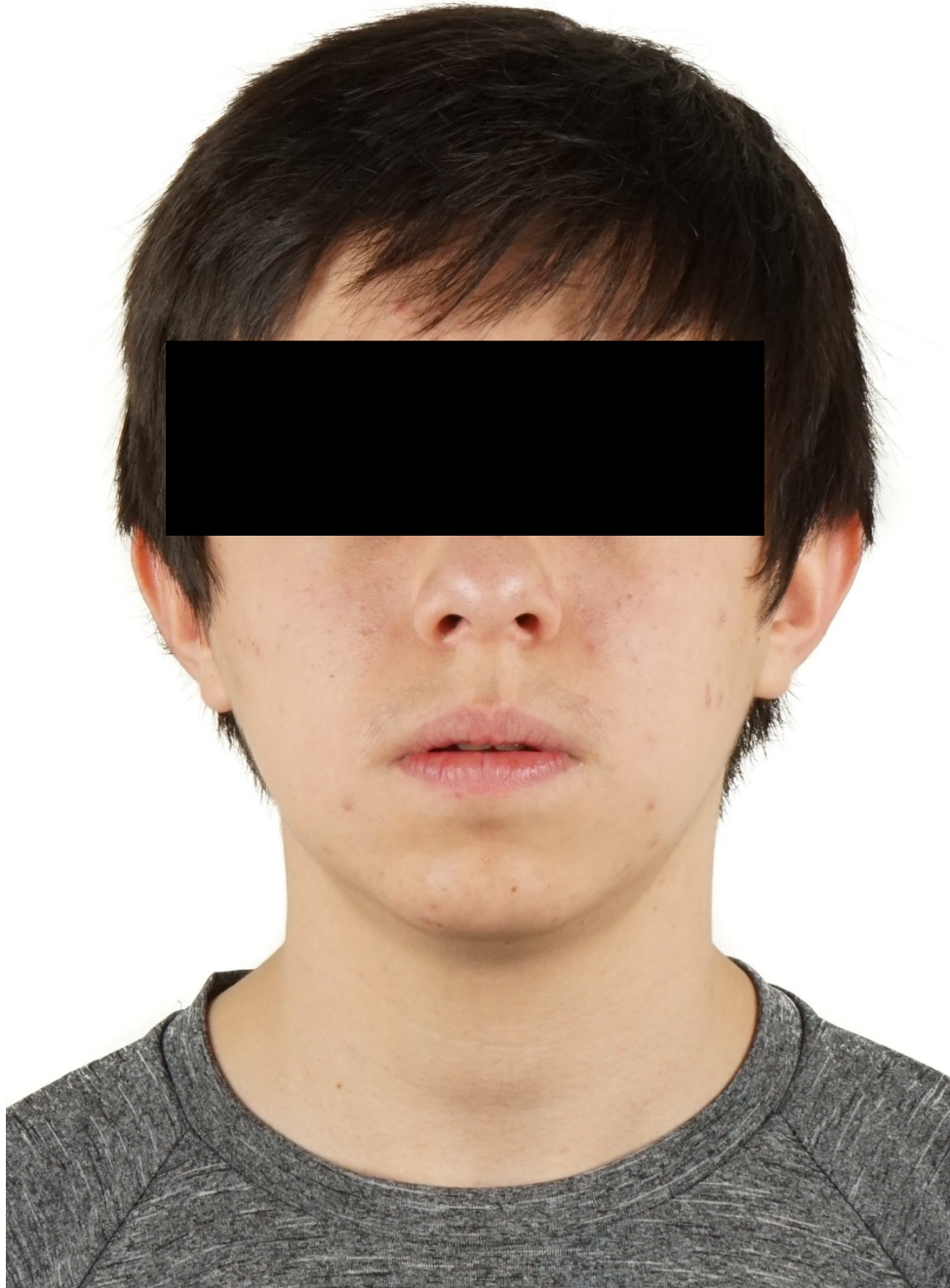


ICF3D

TECNOLOGÍA DIGITAL EN ODONTOLOGÍA

Paciente: Nombre Paciente
Dentista Tratante: Nombre Dr.



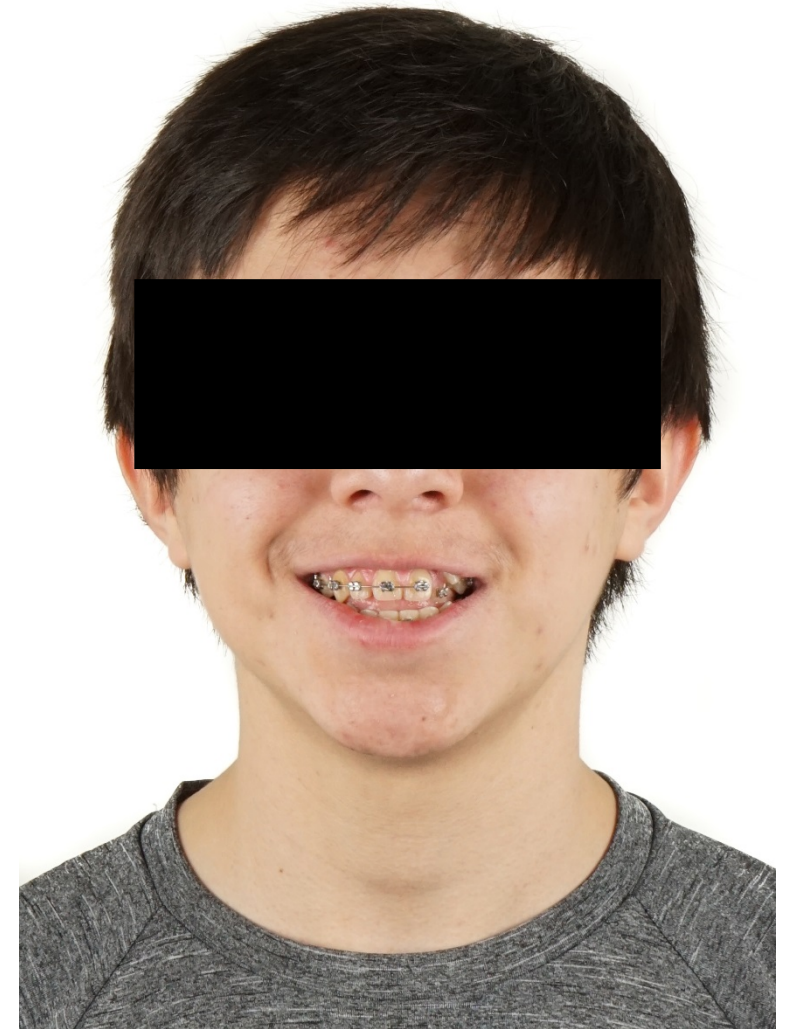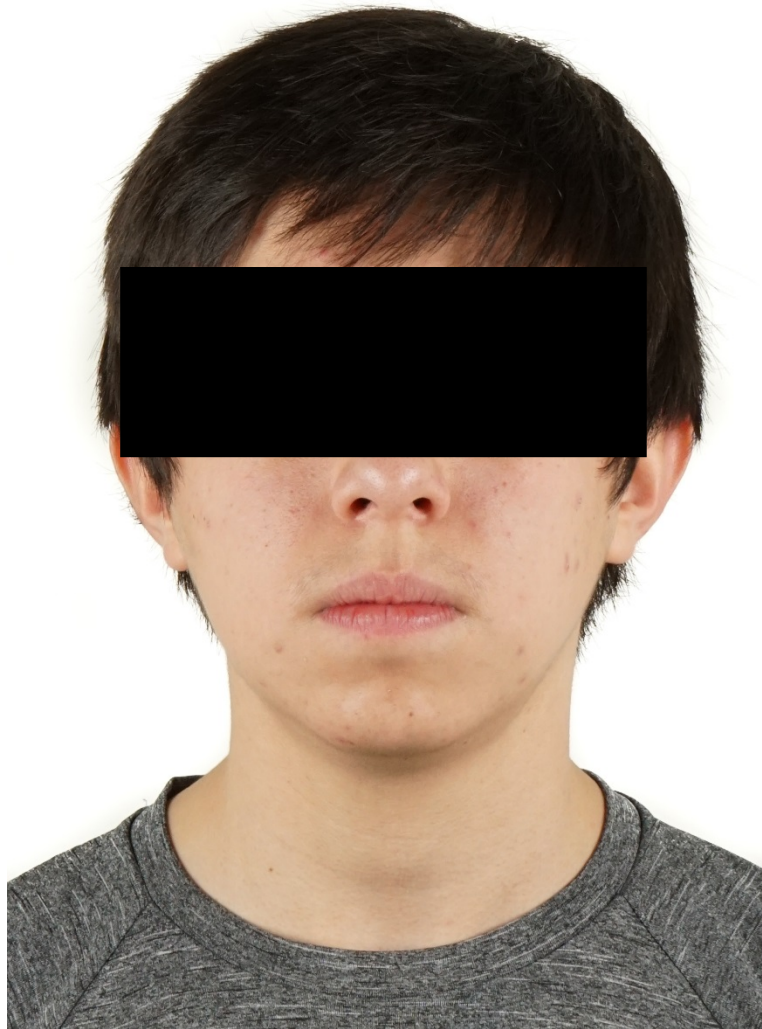ICF3D
TECNOLOGÍA DIGITAL EN ODONTOLOGÍA

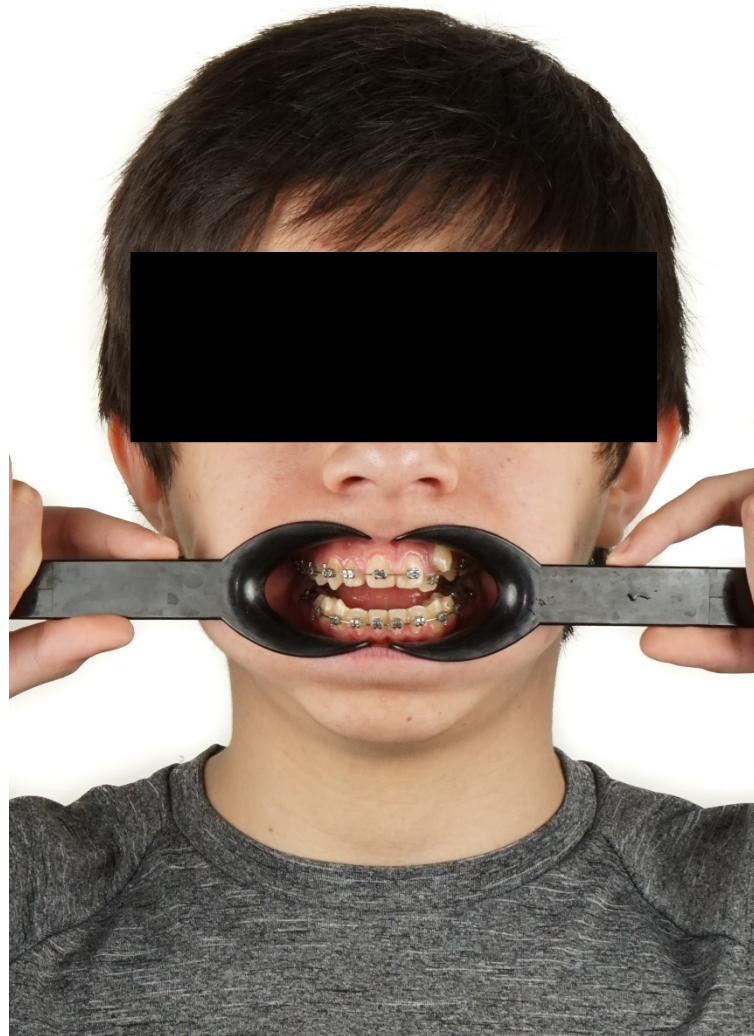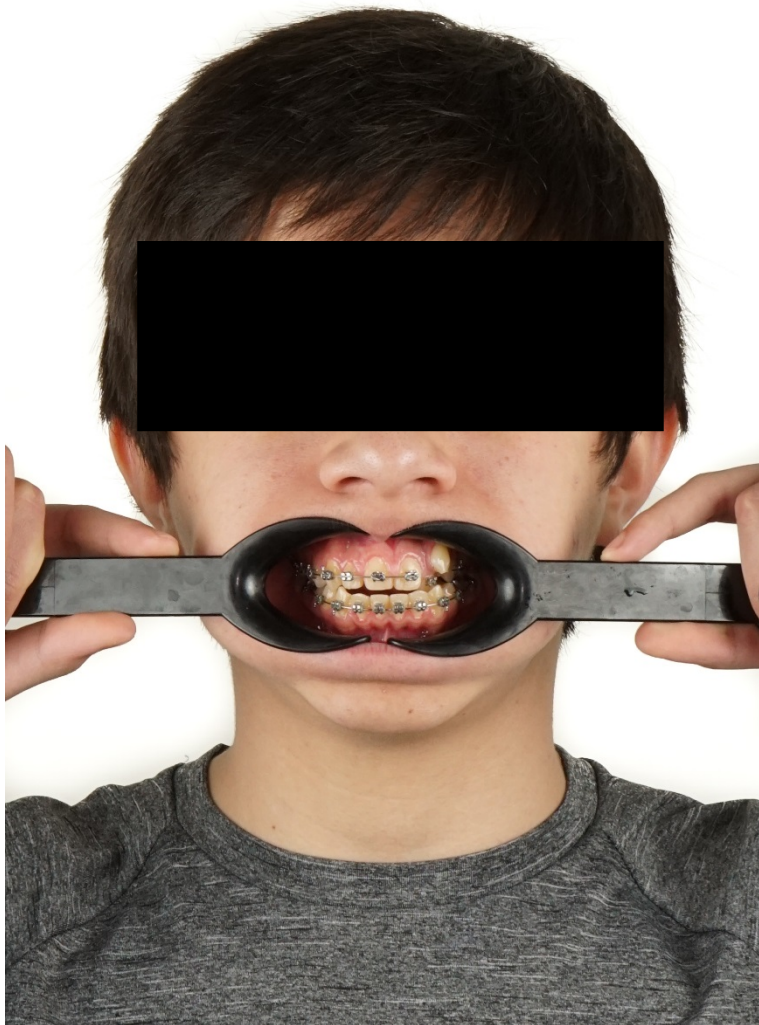Información del caso

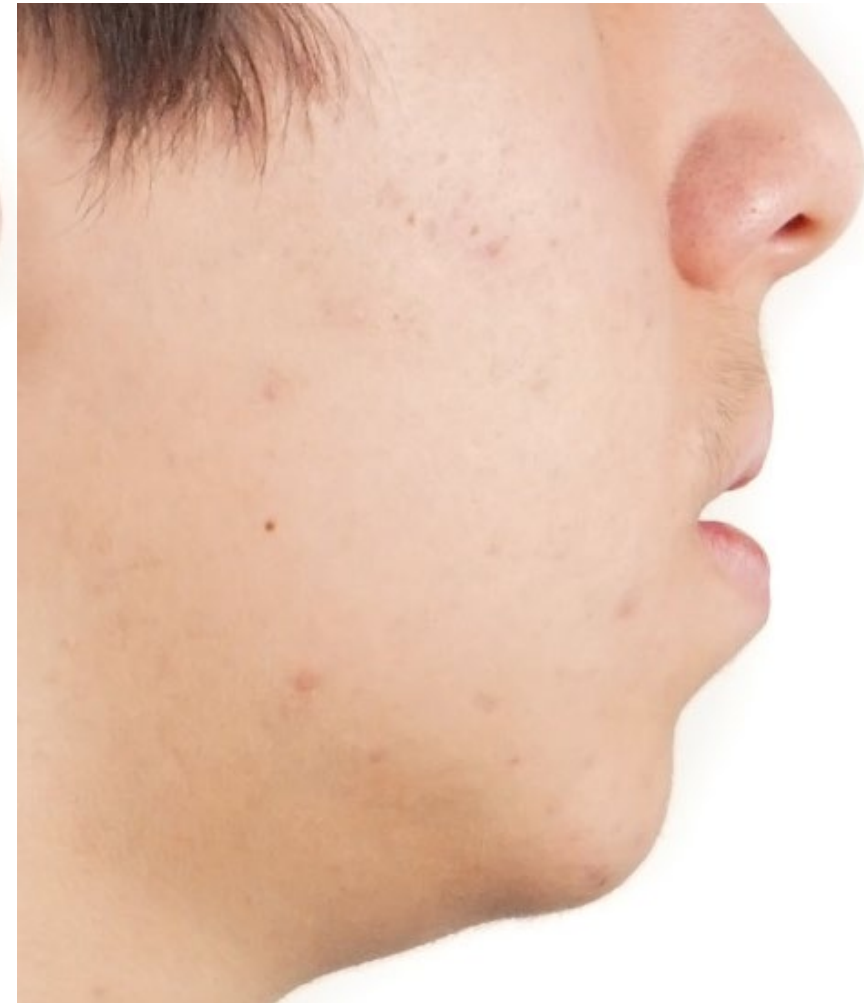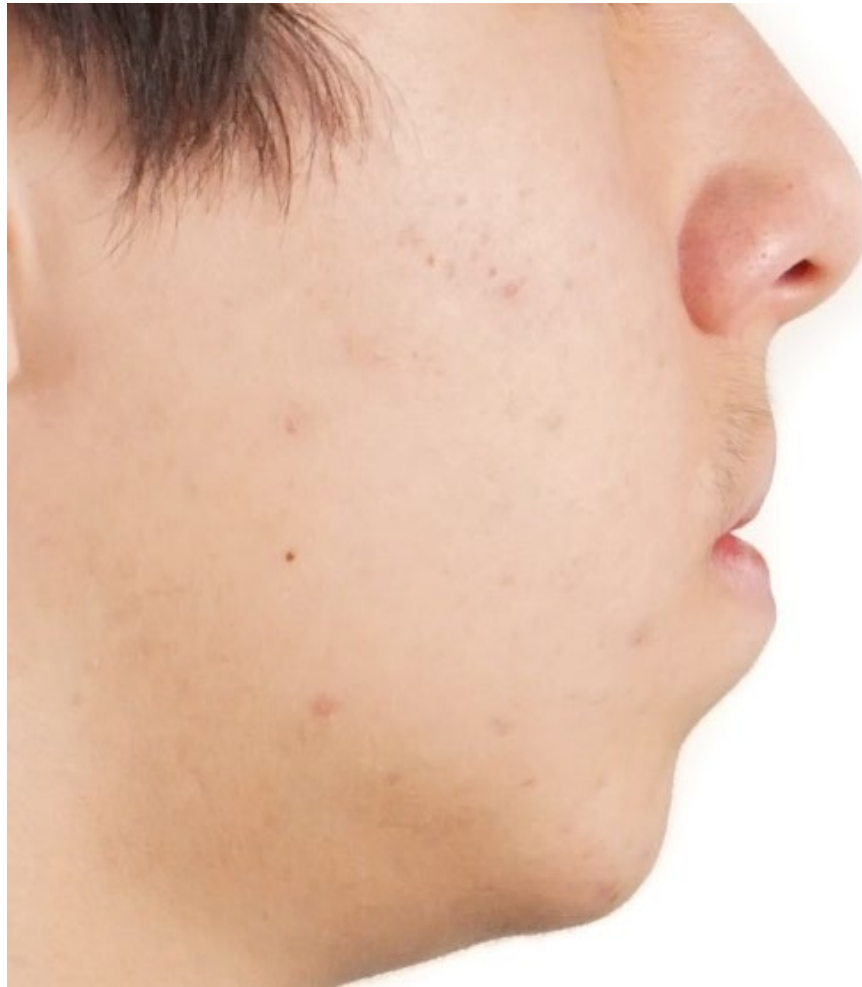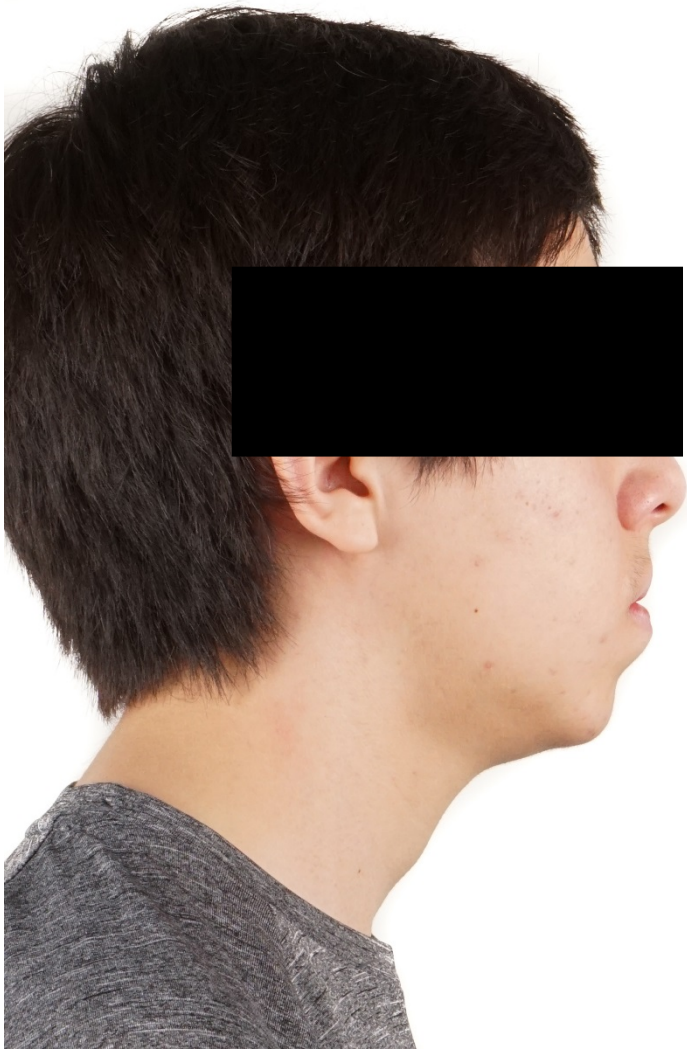Nombre Paciente


F.Nac: 18 de Octubre del 2006

Perfil no coincide con oclusión.

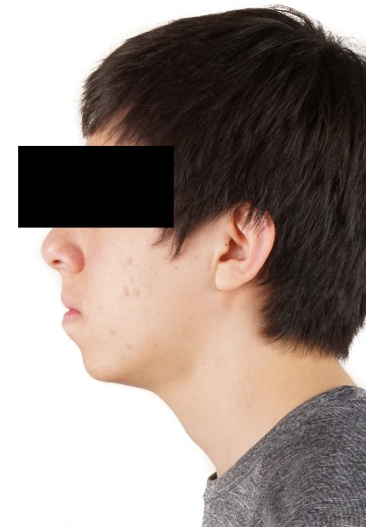
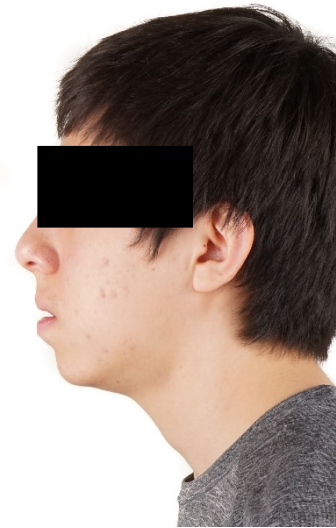
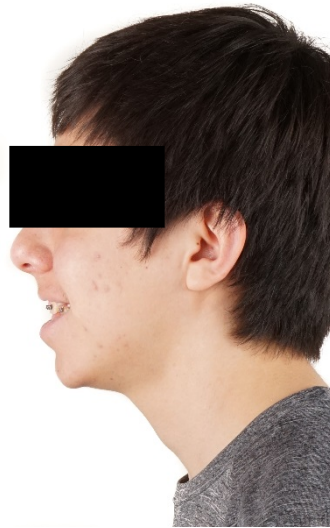
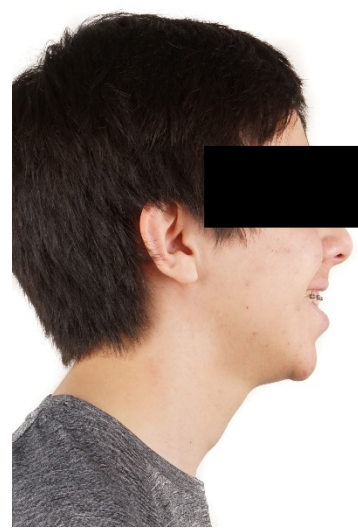
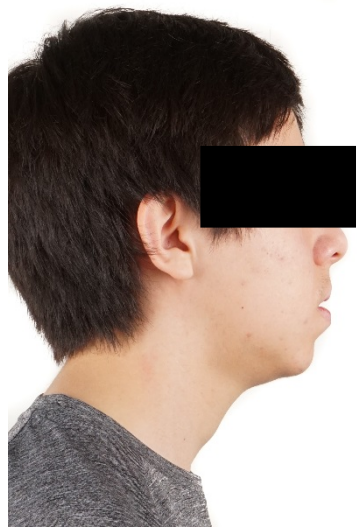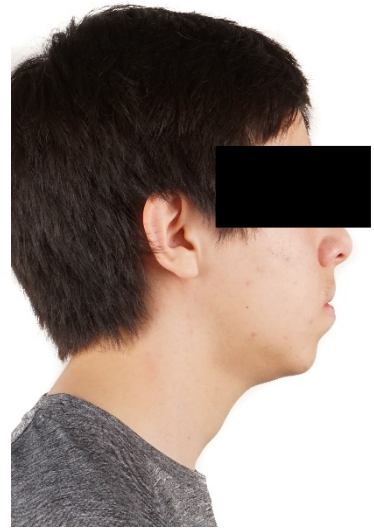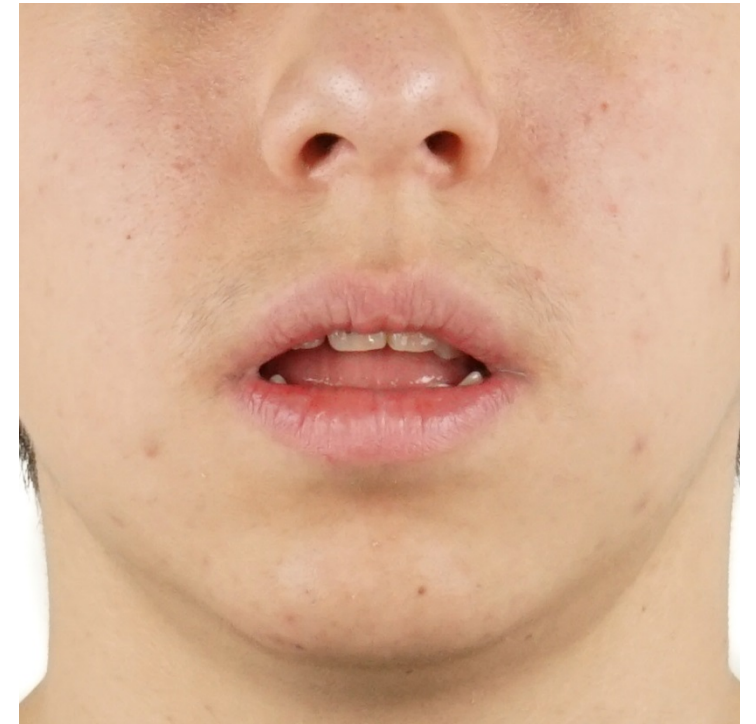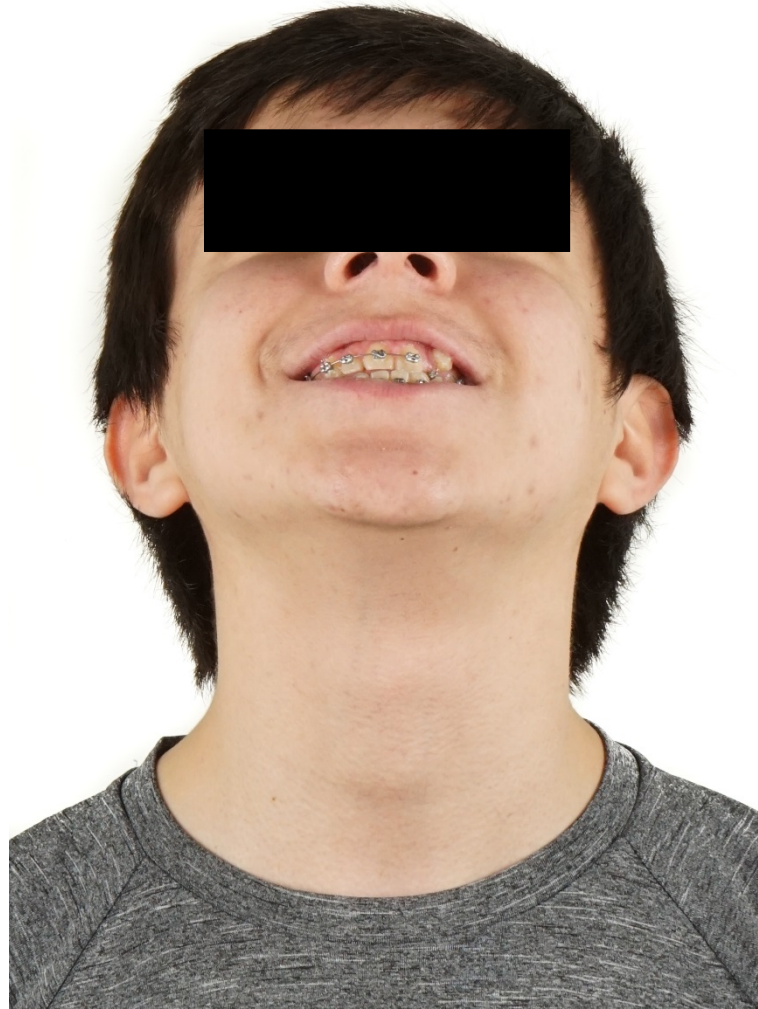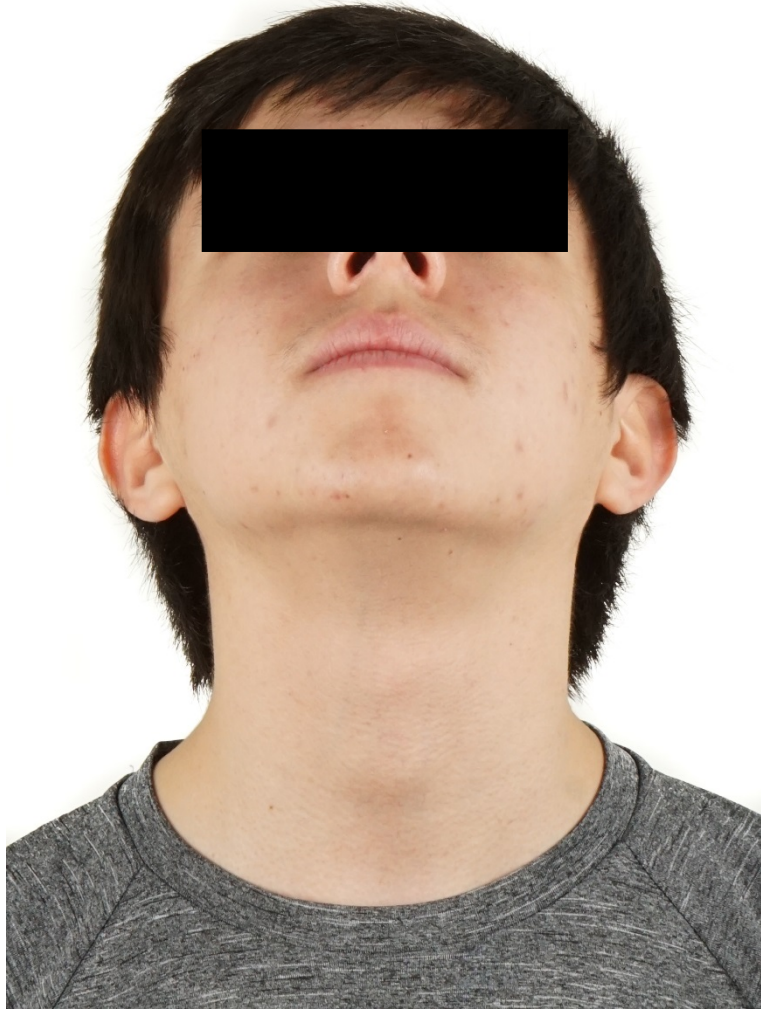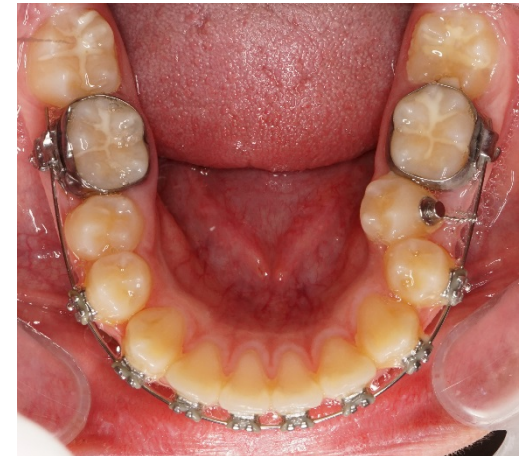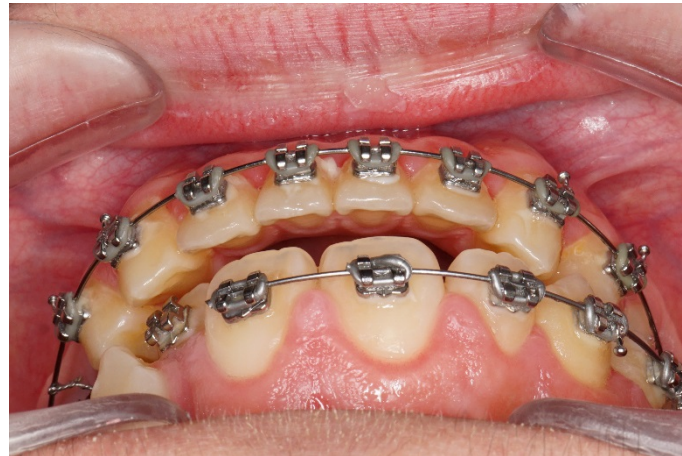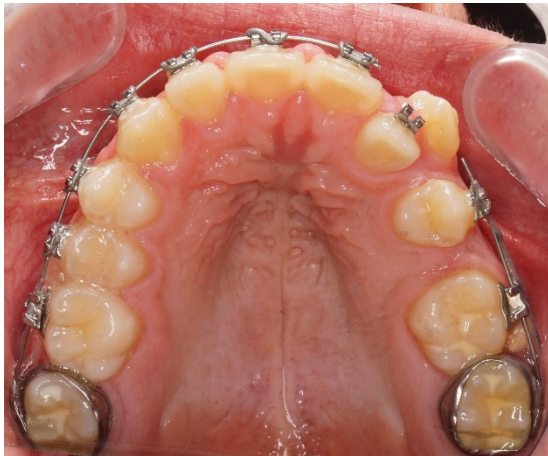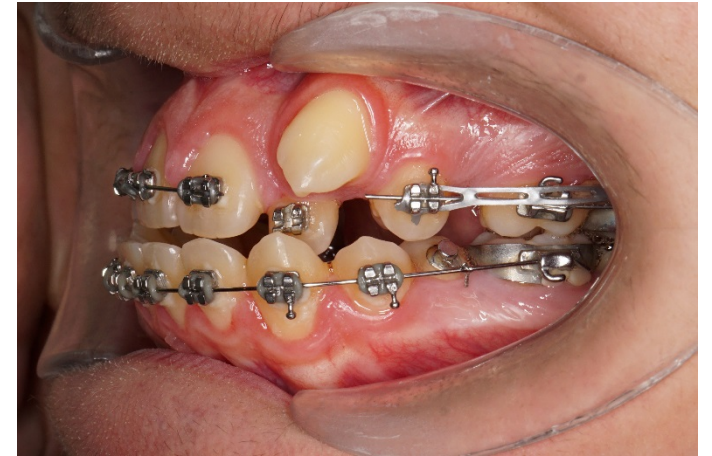
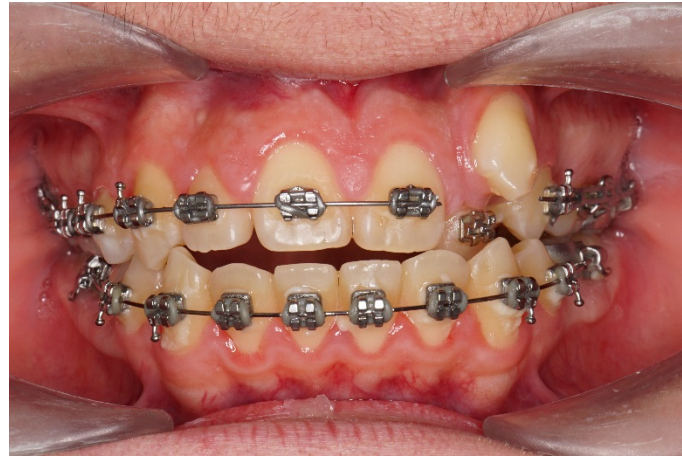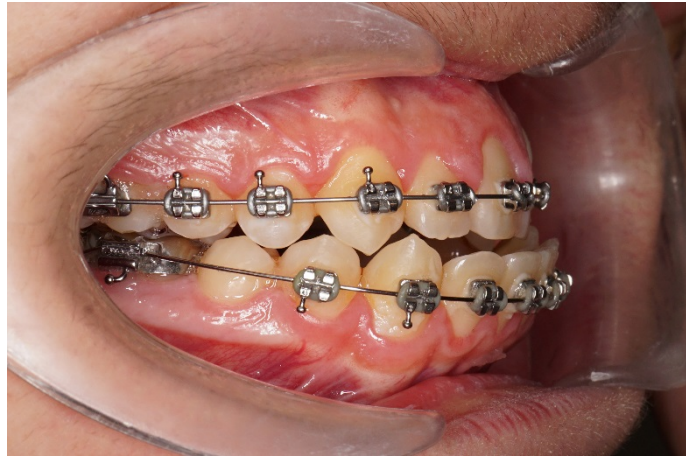


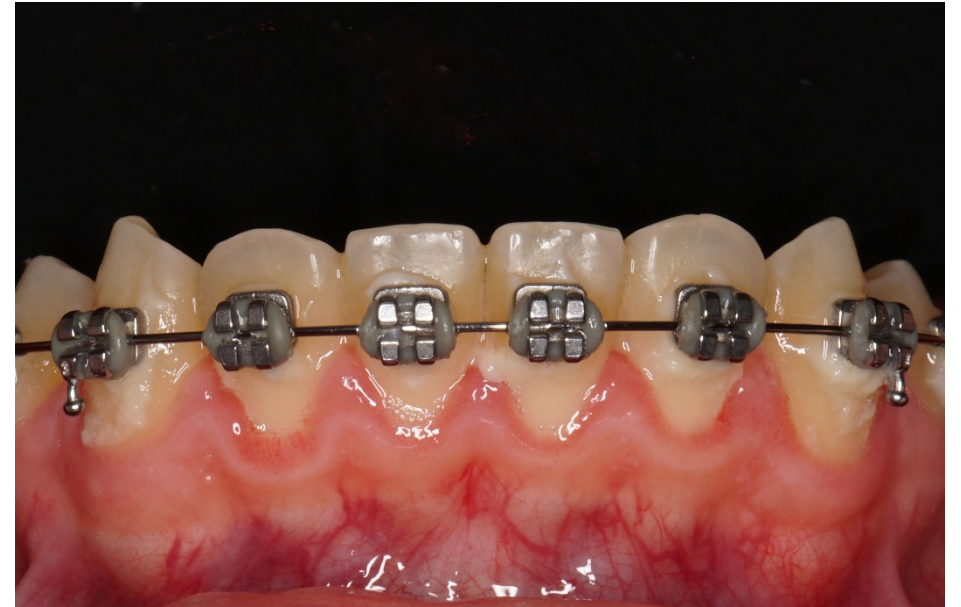


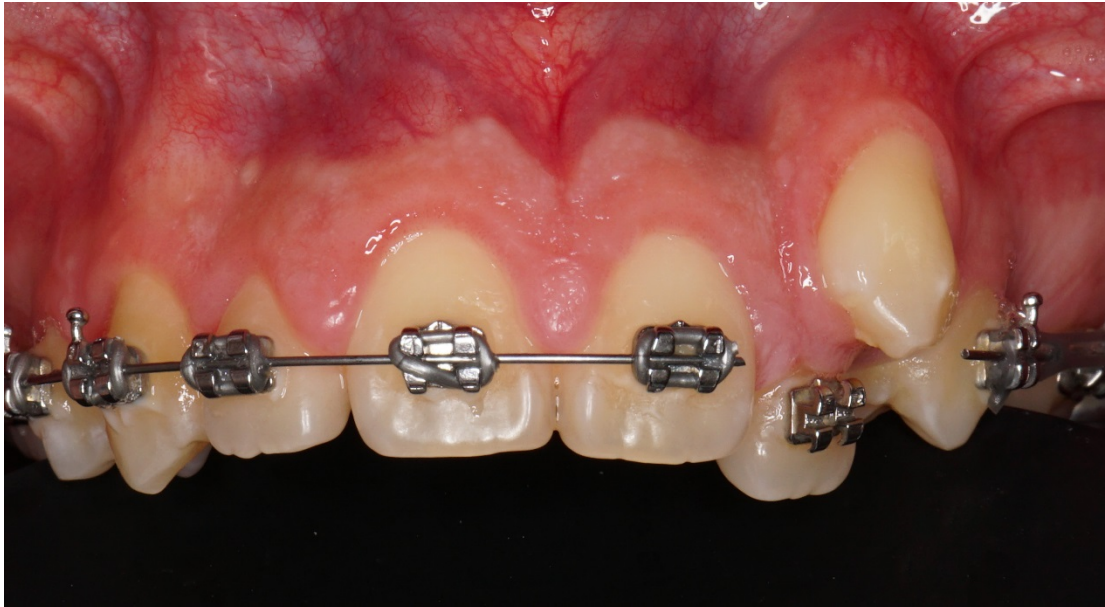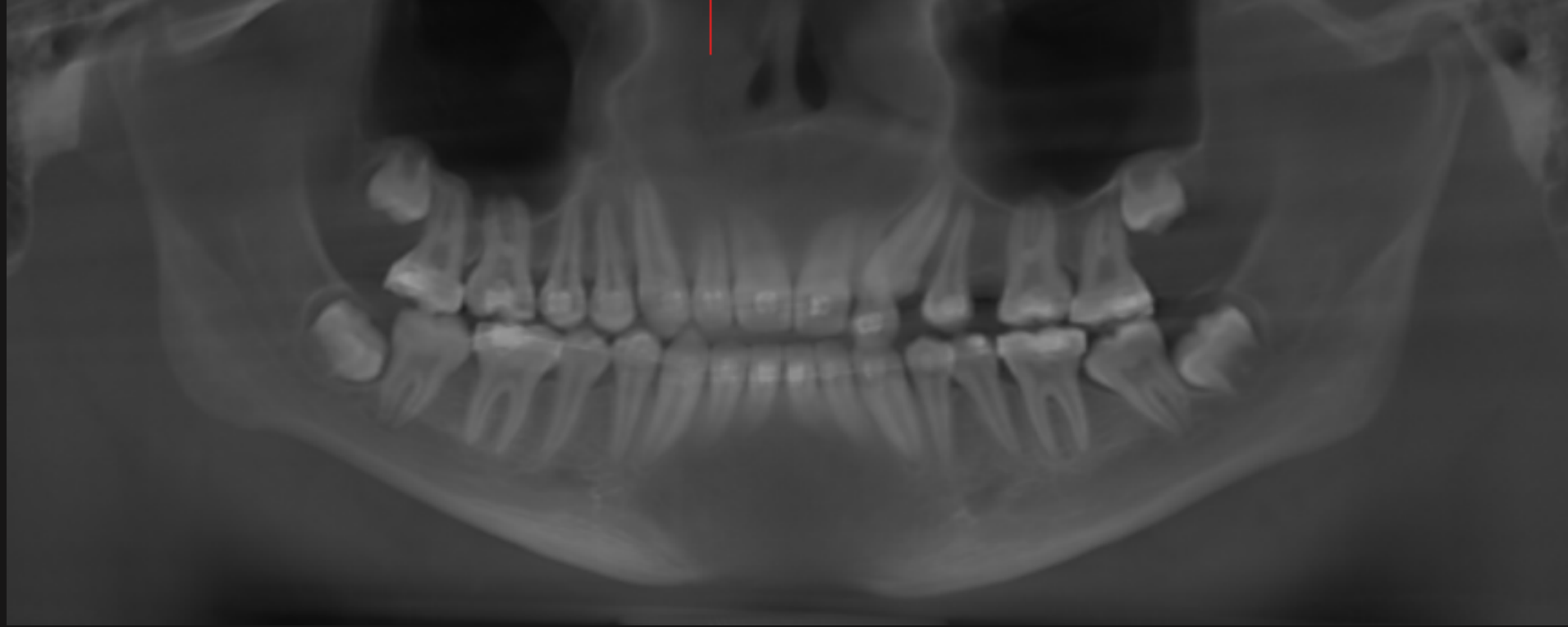ICF3D
TECNOLOGÍA DIGITAL EN ODONTOLÓGIA



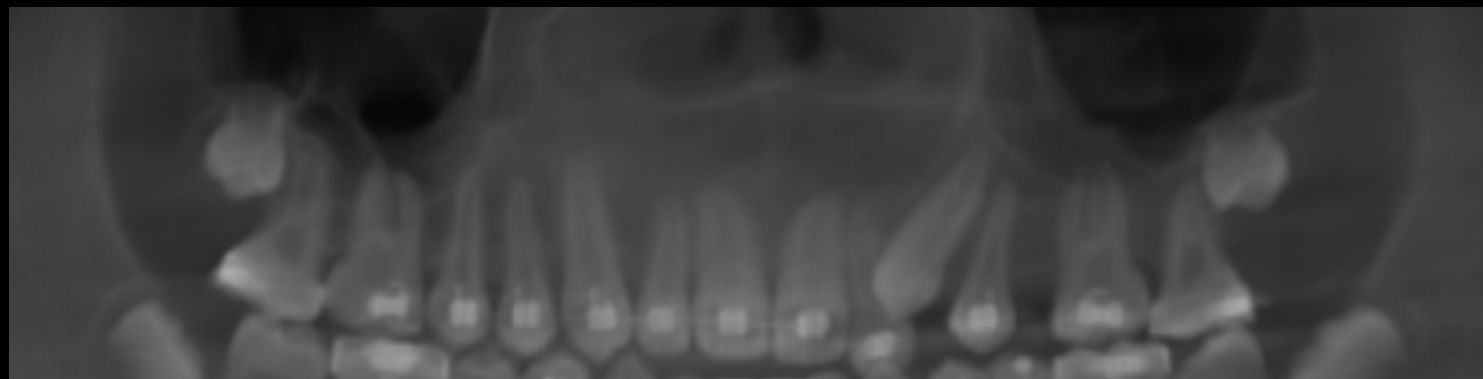








CORTES EJE DENTARIO SUPERIOR



DTE 1.8

DTE 1.7

DTE 1.6

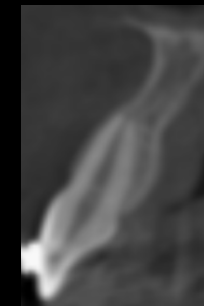
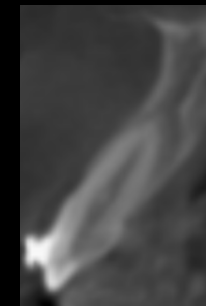
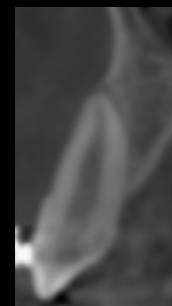
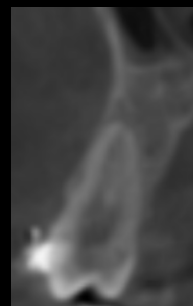

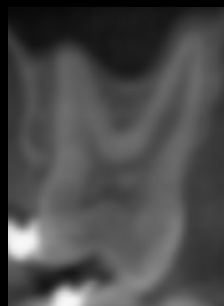
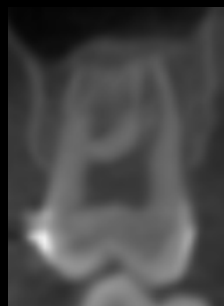
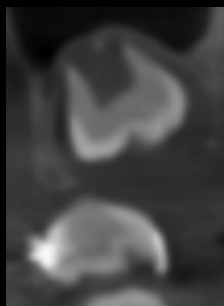
DTE 1.5

DTE 1.4

DTE 1.3

DTE 1.2

DTE 1.1



DTE 2.1

DTE 2.2

DTE 2.3

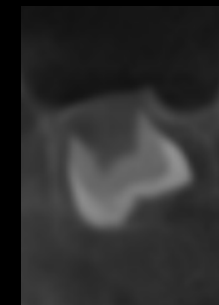
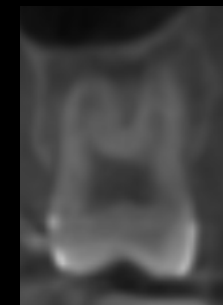
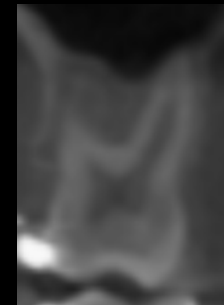
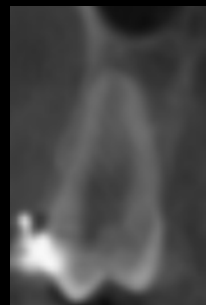
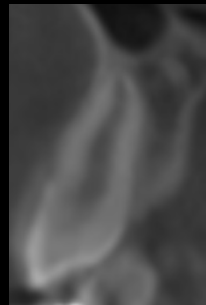
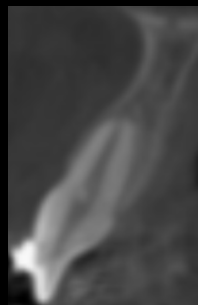
DTE 2.4

DTE 2.5

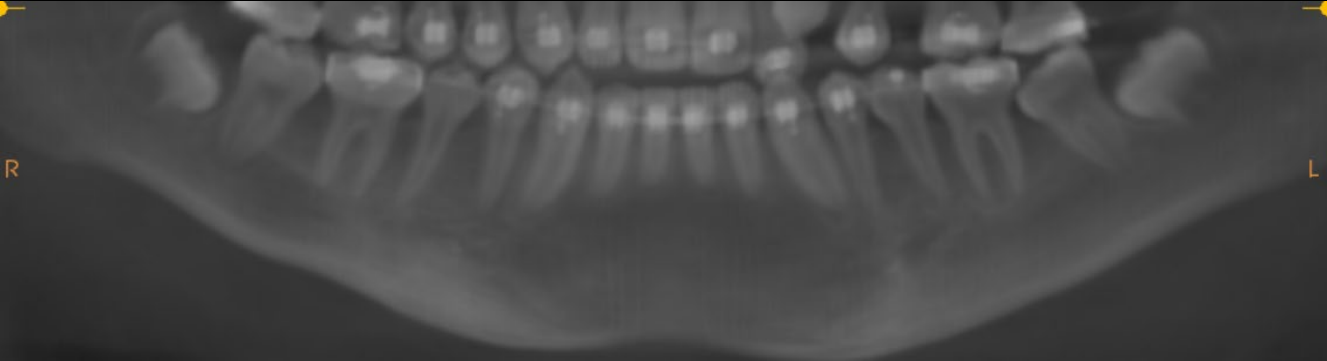
DTE 2.6

DTE 2.7

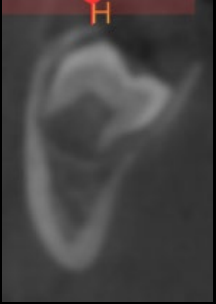
DTE 2.8



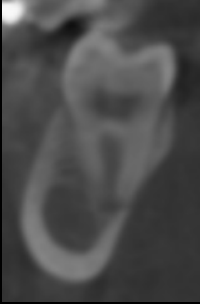CORTES EJE DENTARIO INFERIOR



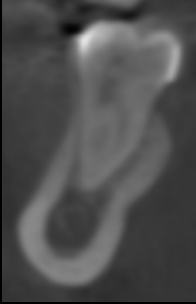
DTE 4.8



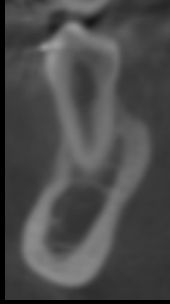
DTE 4.7



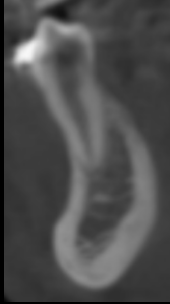
DTE 4.6



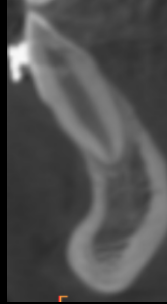
DTE 4.5



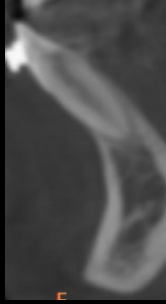
DTE 4.4



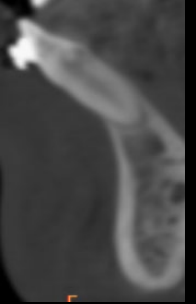
DTE 4.3



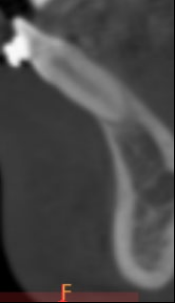
DTE 4.2



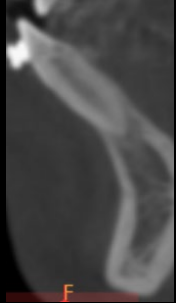DTE 4.1



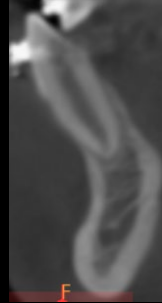
DTE 3.1



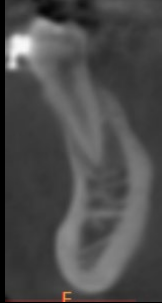
DTE 3.2



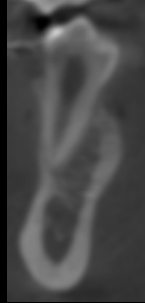
DTE 3.3



DTE 3.4



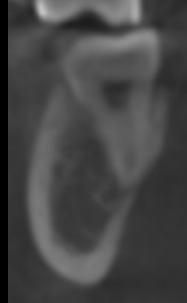DTE 3.5



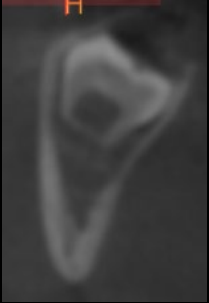DTE 3.6



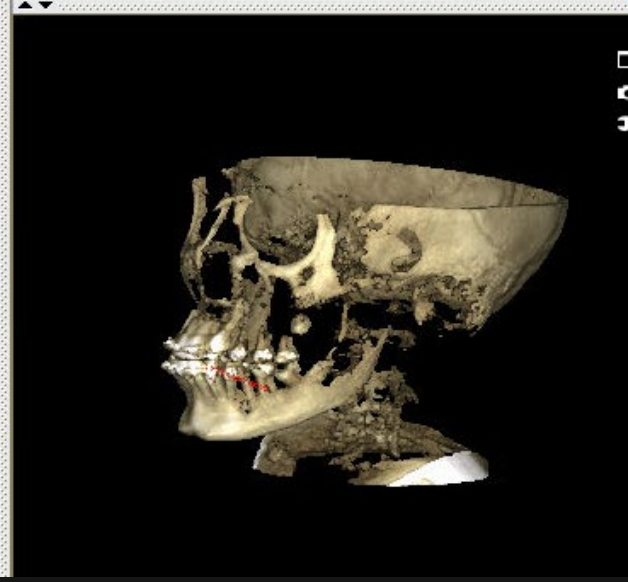
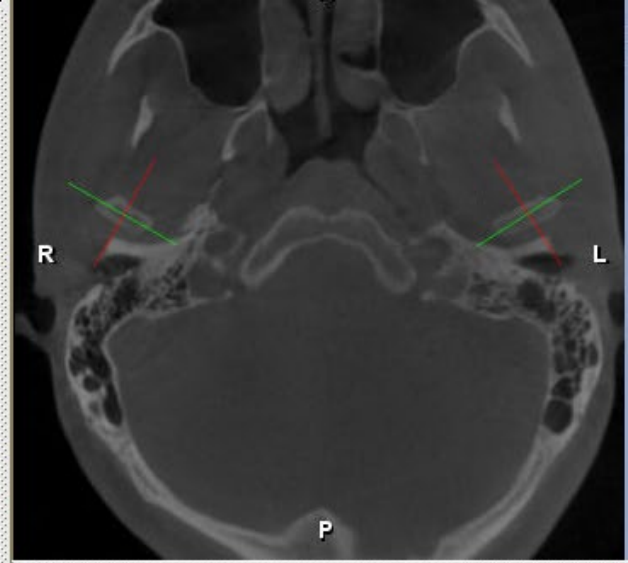
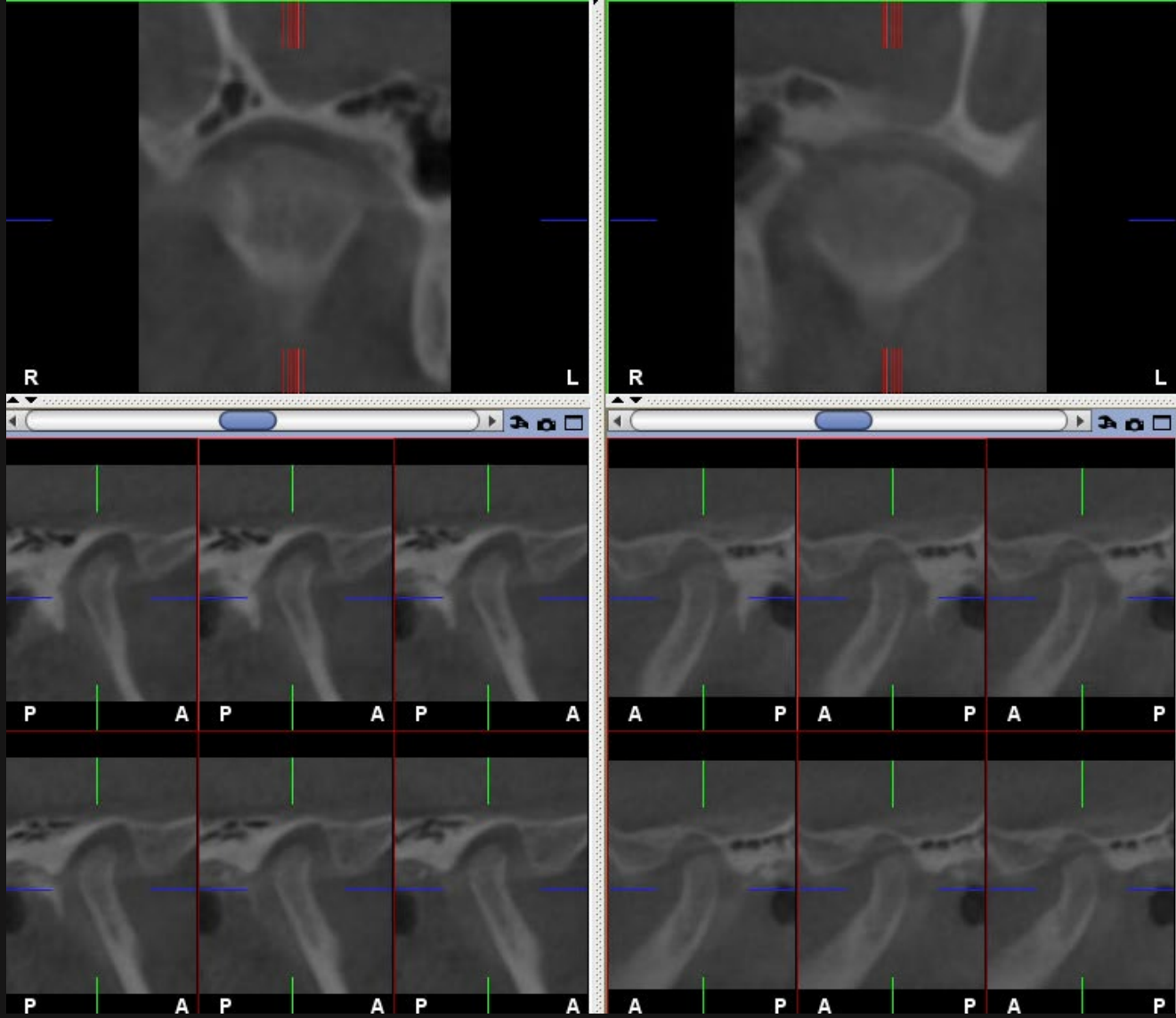
DTE 3.7



DTE 3.8

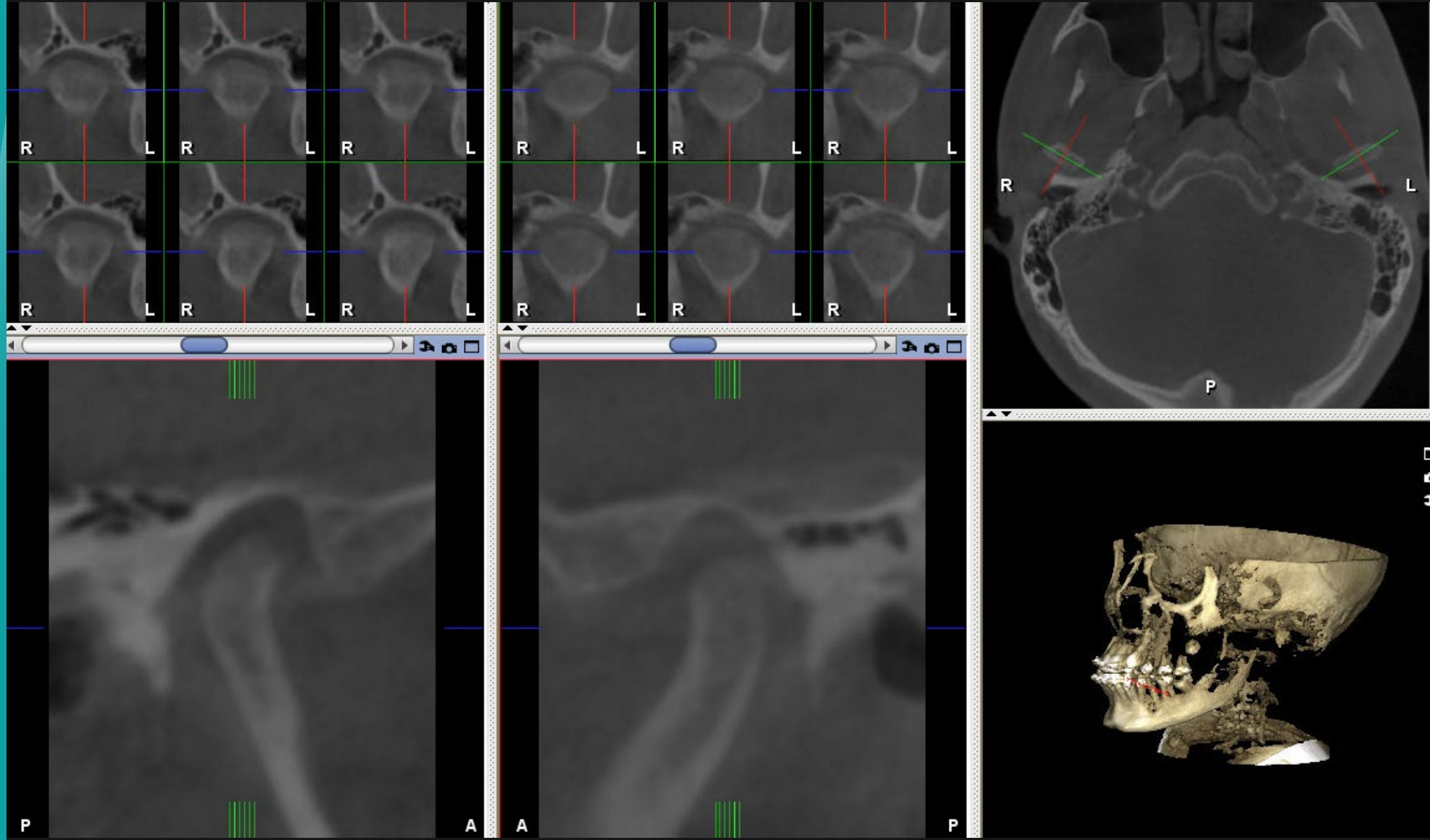


Estudio de la ATM Cortes Sagitales



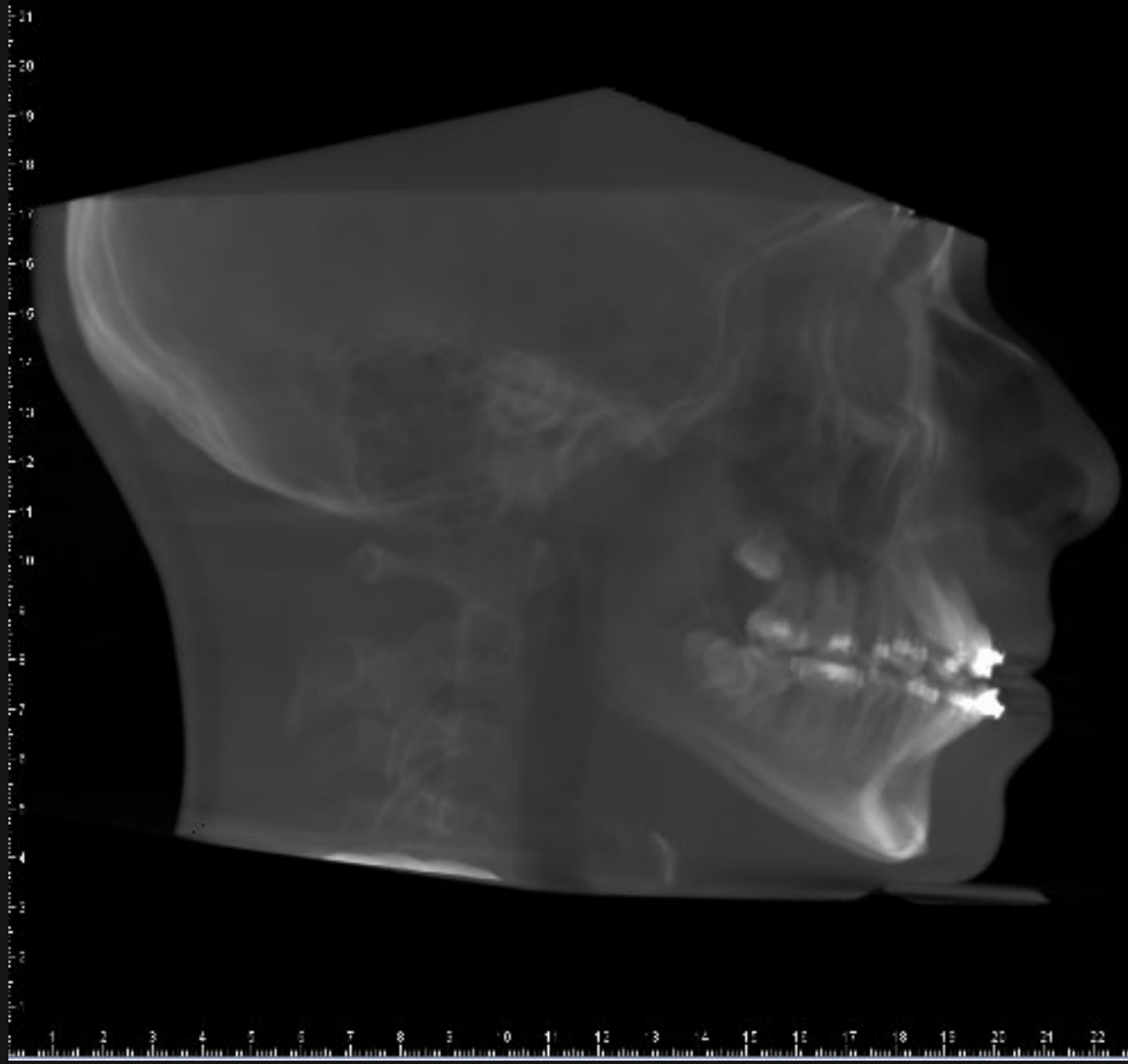
ICF3D

Estudio de la ATM Cortes Coroneles



ICF3D

Telerradiografía de Perfil





ICF3D

Paciente: Martin Ramos Vellela

Fecha: 25-07-2021

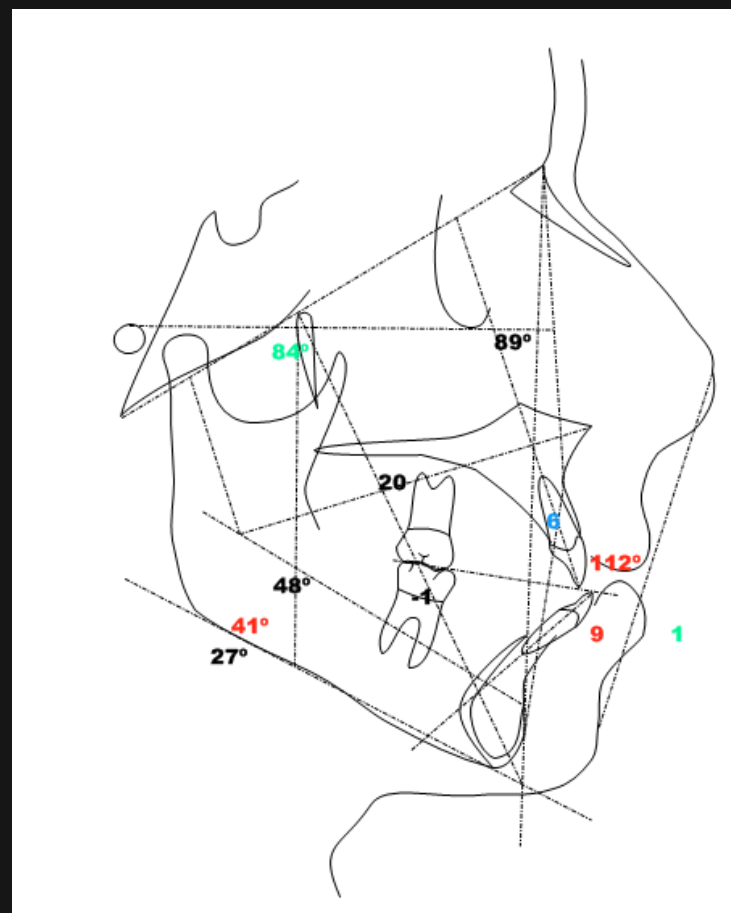
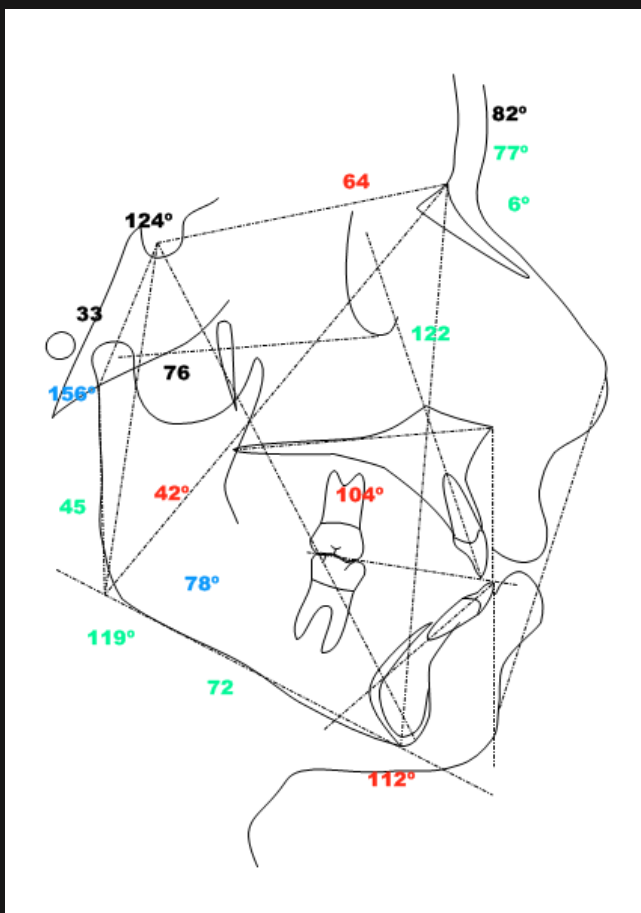
Edad Dental: 14A 9M Sexo: Hombre

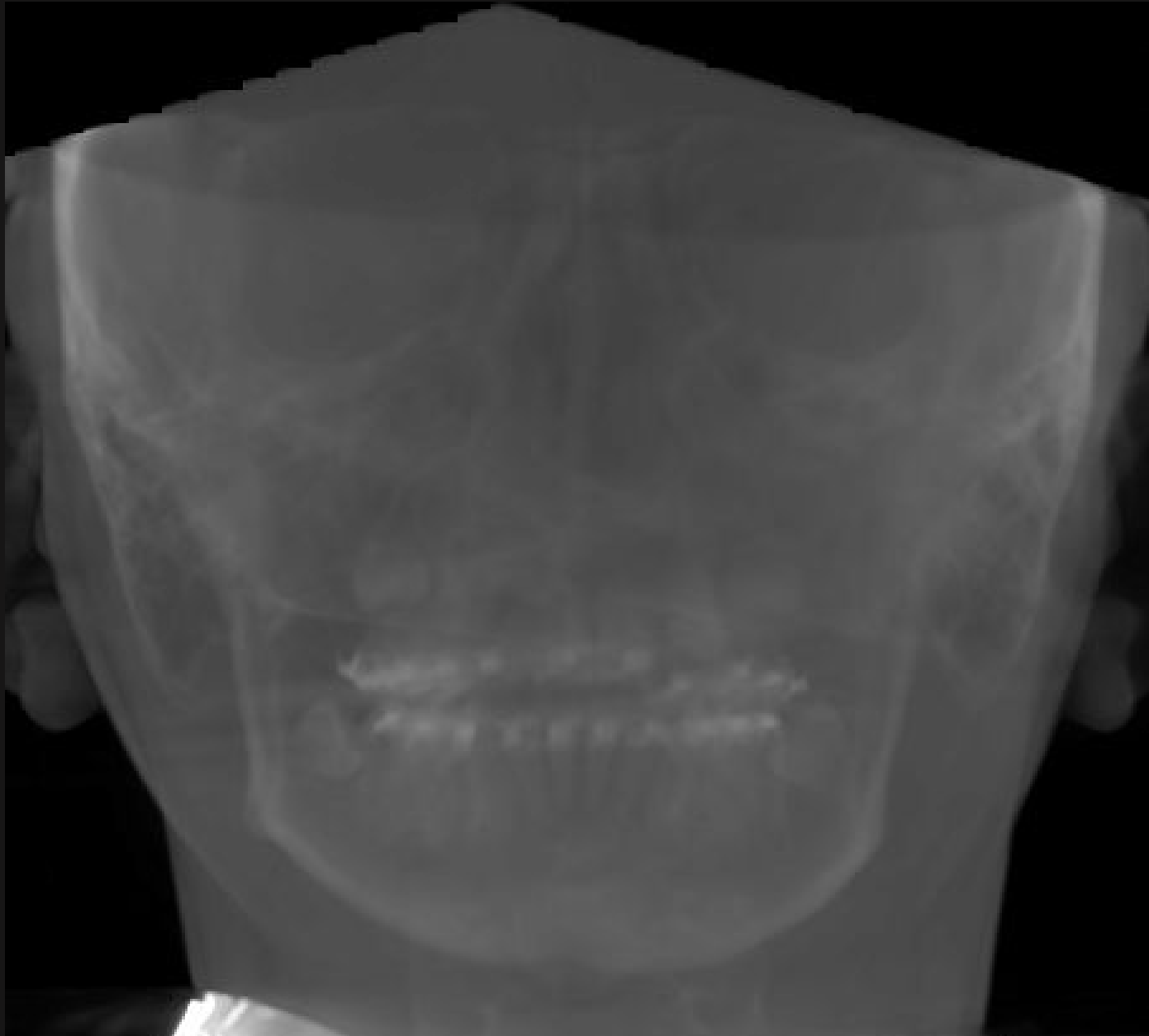
Análisis de Ricketts

Cefalometría Lateral

Pretratamiento

Vert: 0,1 MesoFacial.

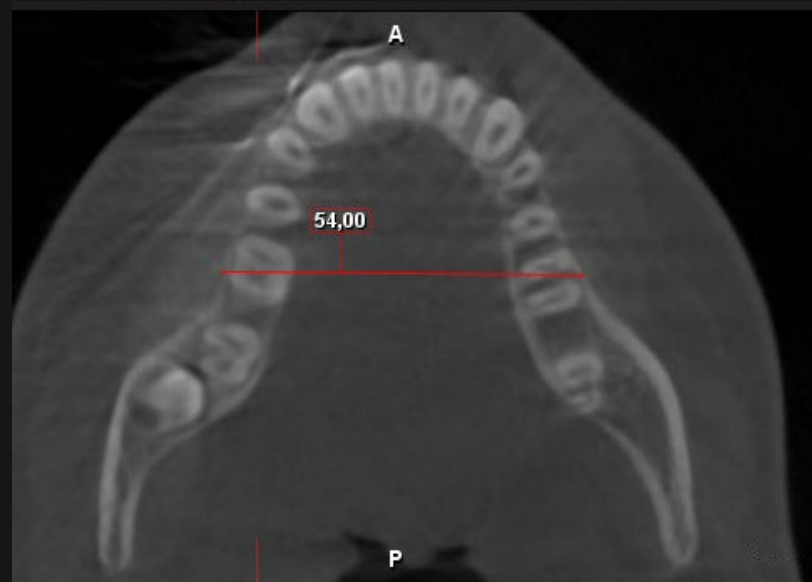
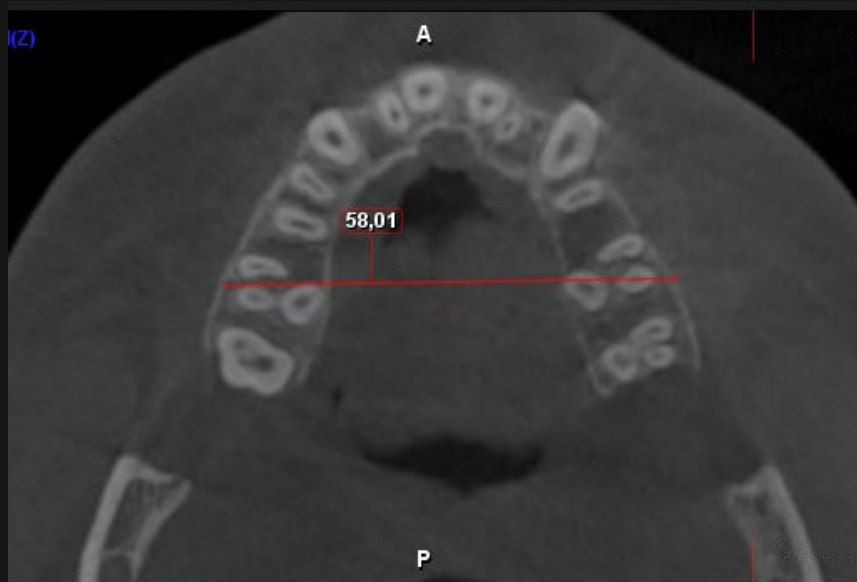
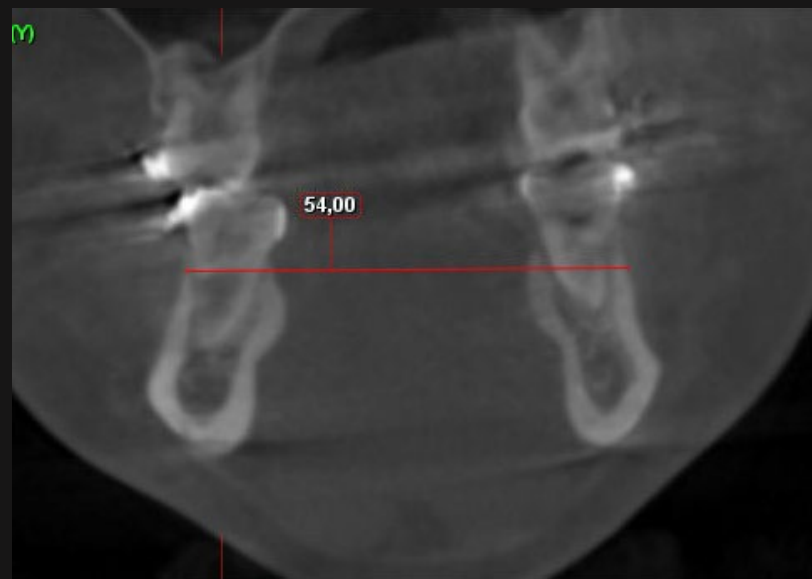
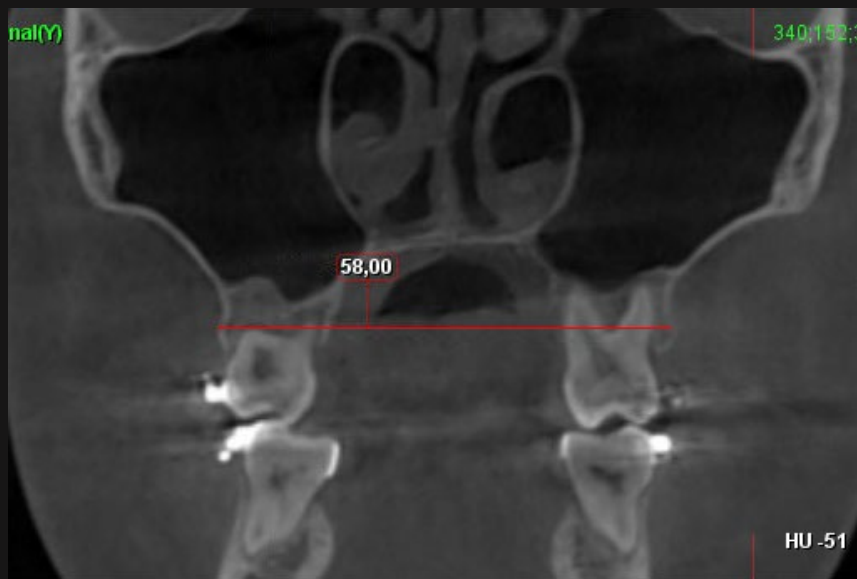



ICF3D

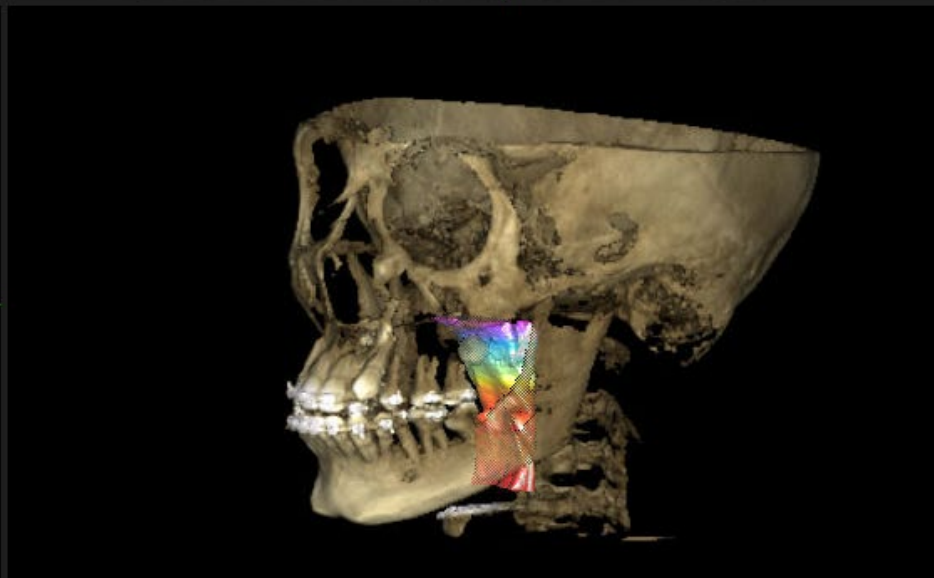
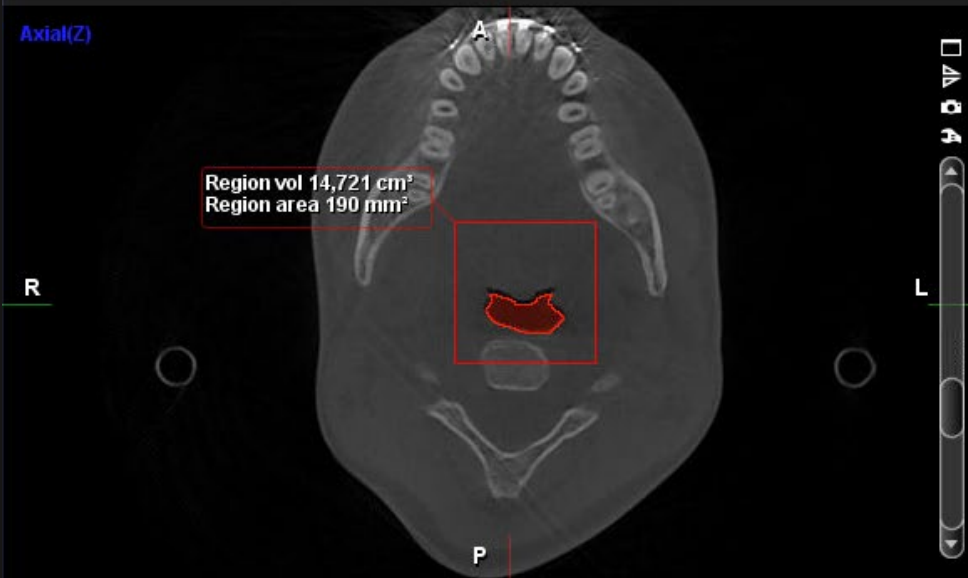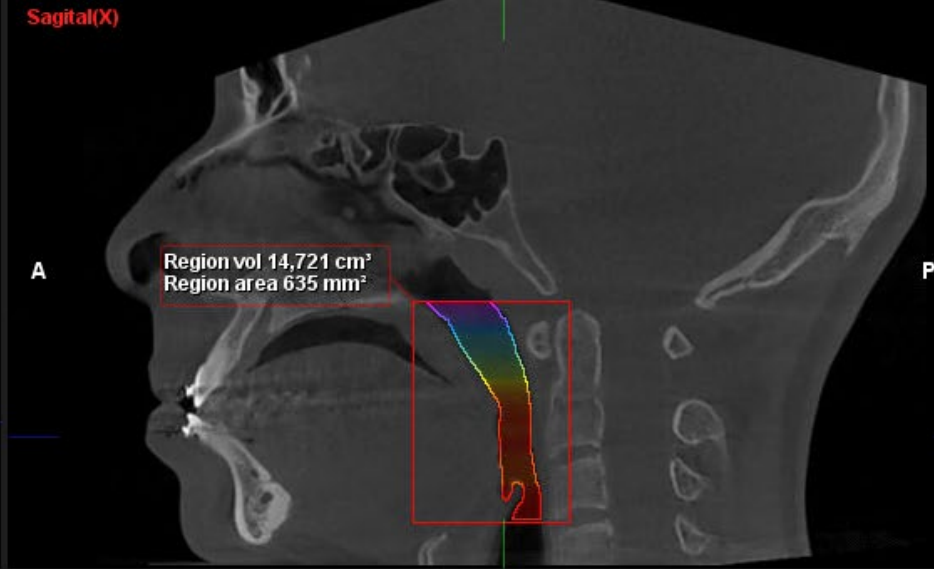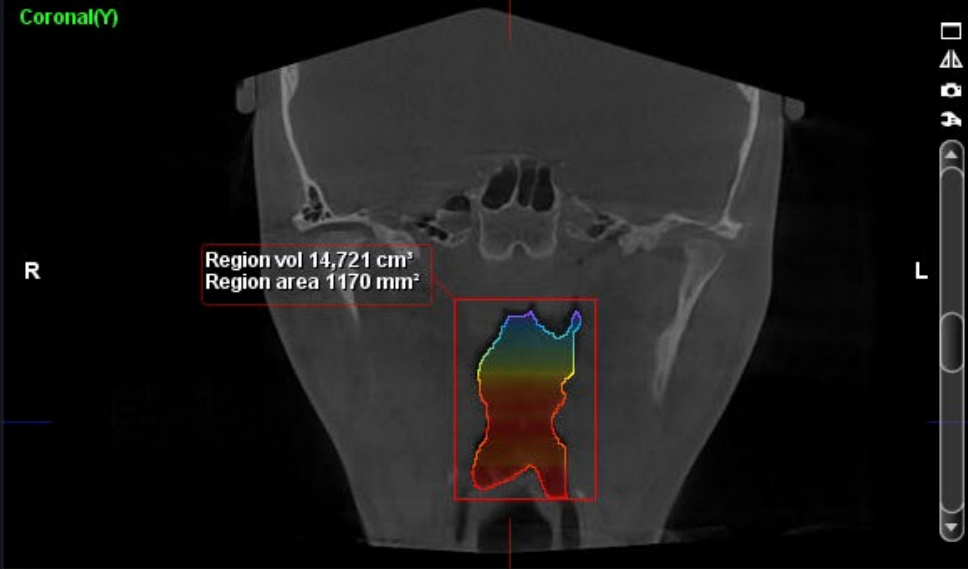


ICF3D



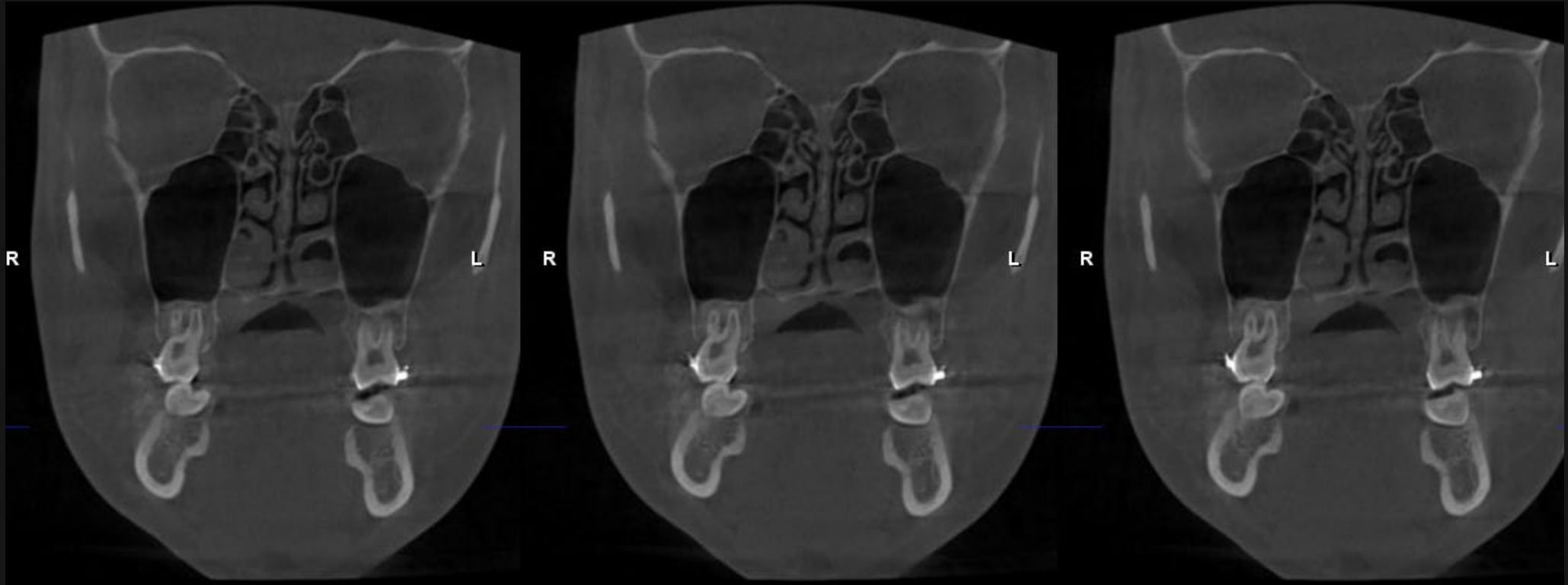

ICF3D

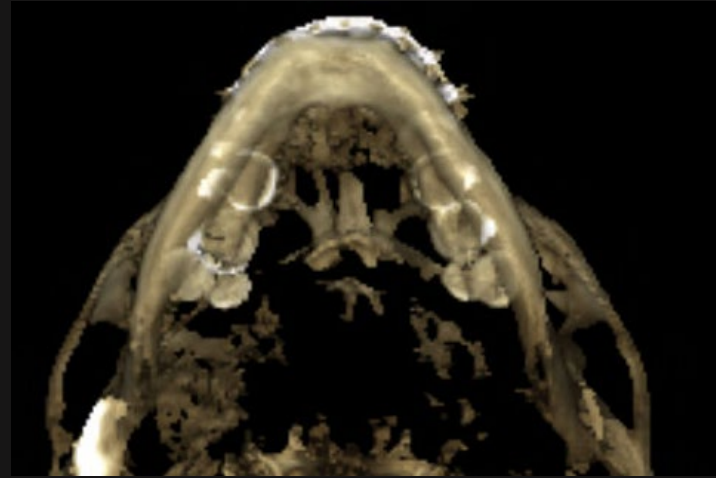
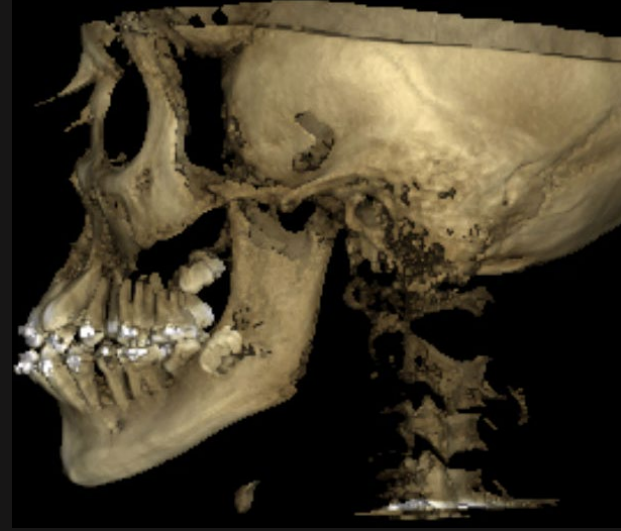
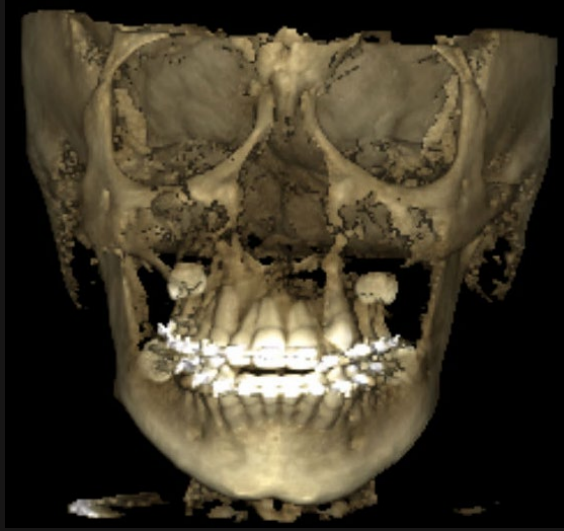
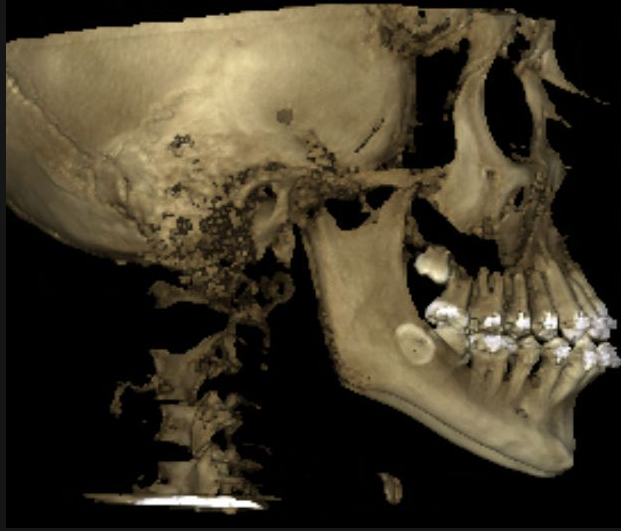



ICF3D



Reconstrucción 3D



ICF3D